

Akutes Abdomen

Dr. Ignaz Schneider

Maßnahmen in der Poliklinik



Akutes Abdomen

Leitsymptome

- **akuter heftiger Leibschmerz**
- **Peritonitis mit Störung der Darmfunktion**
- **Kreislaufdysregulation (Schock)**



Akutes Abdomen

Ursachen

- **Perforation eines Hohlorgans**
- **Entzündung**
- **Ileus**
- **intraabdominelle Spontanblutung**
- **viscerale Durchblutungsstörung**



Akutes Abdomen

Häufigste chirurgische Ursachen

- **Appendicitis**
- **Ileus**
- **Gallenblasen/Gallenwege**
- **Ulcusperforation**
- **Pancreatitis**
- **Darmperforation (Sigma)**

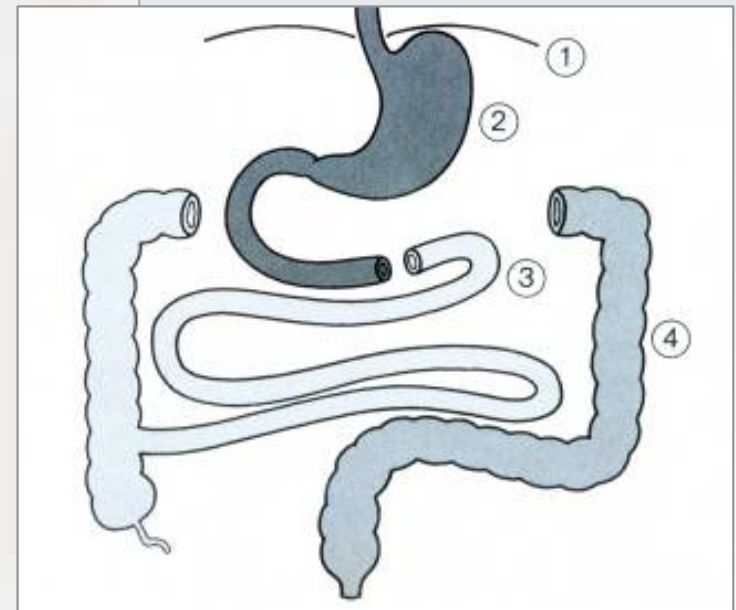
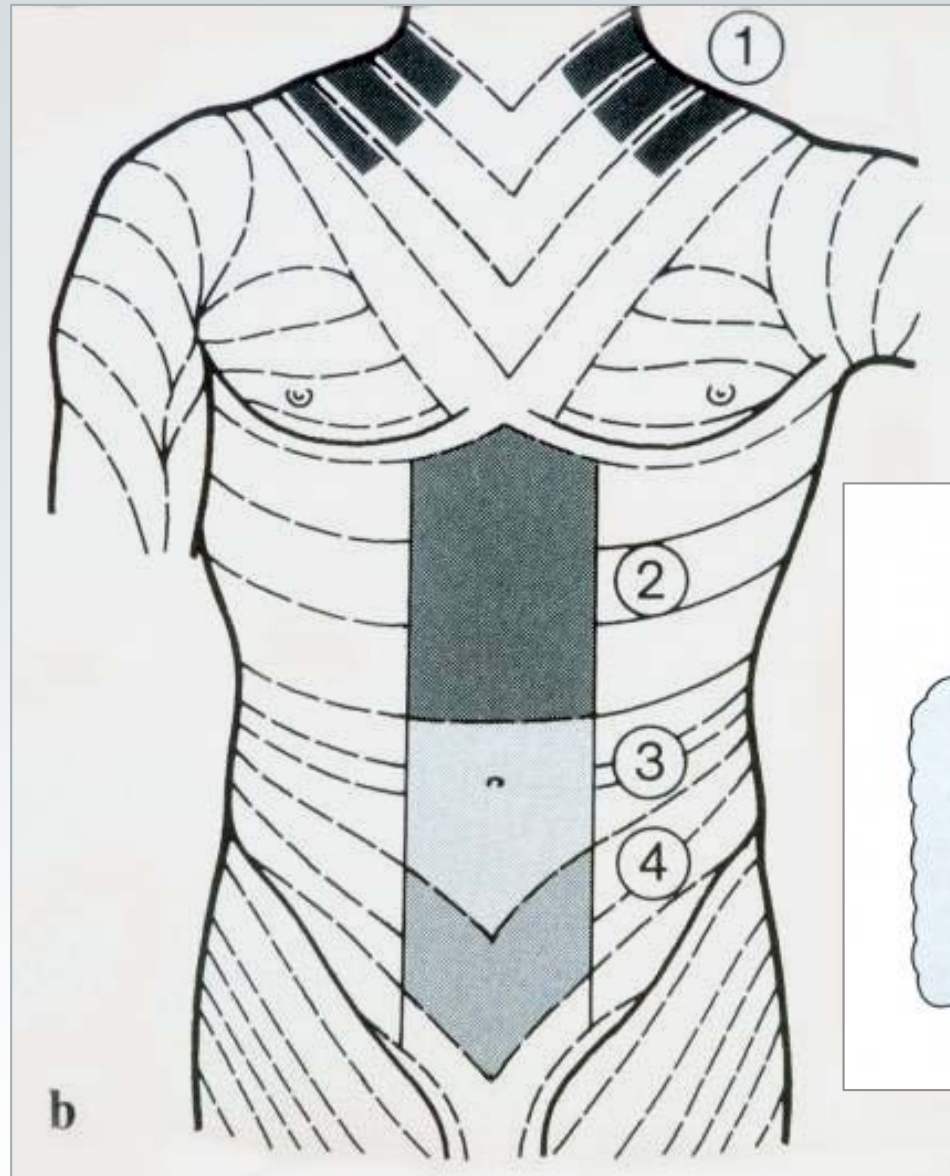

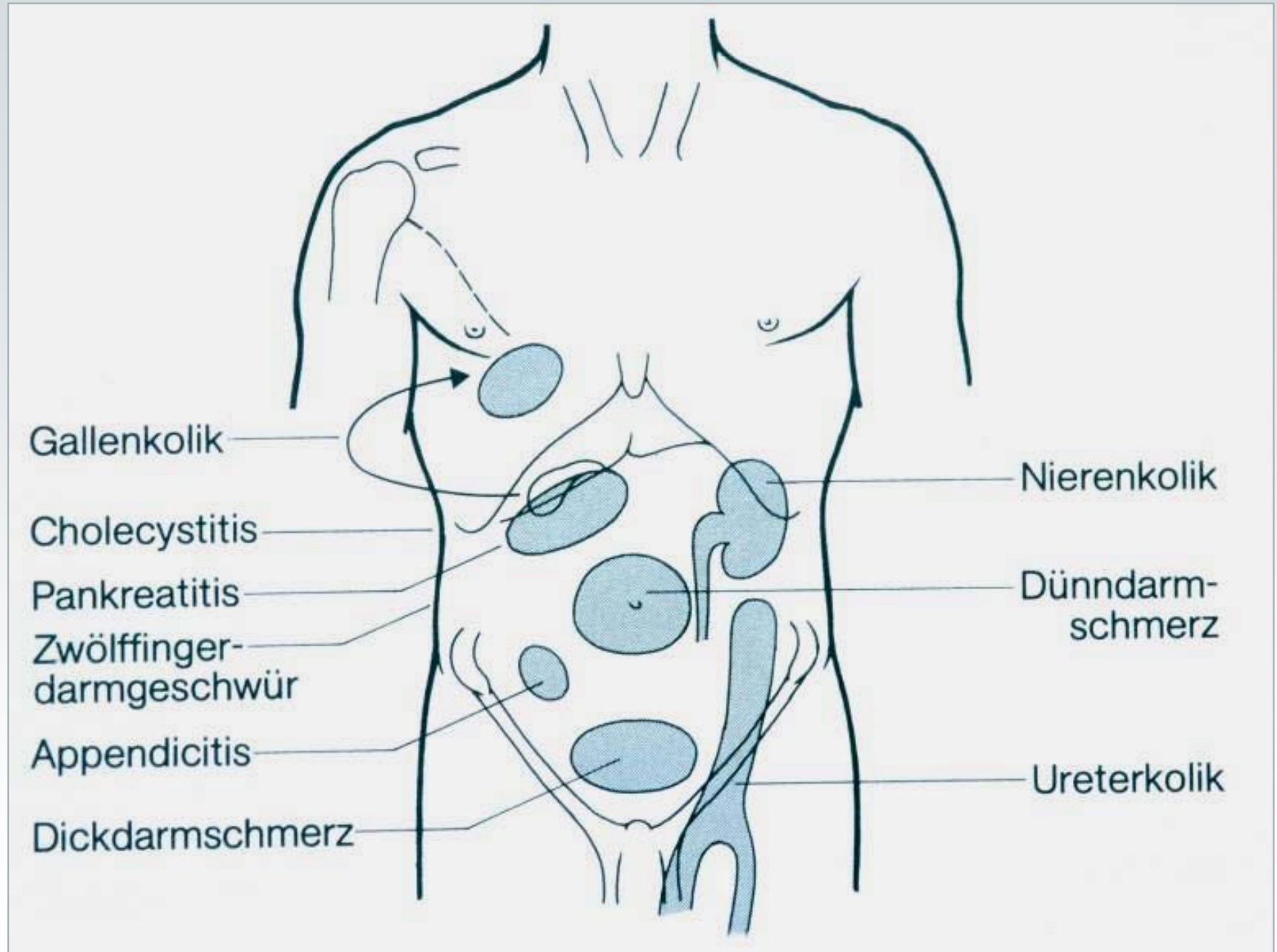
Akutes Abdomen

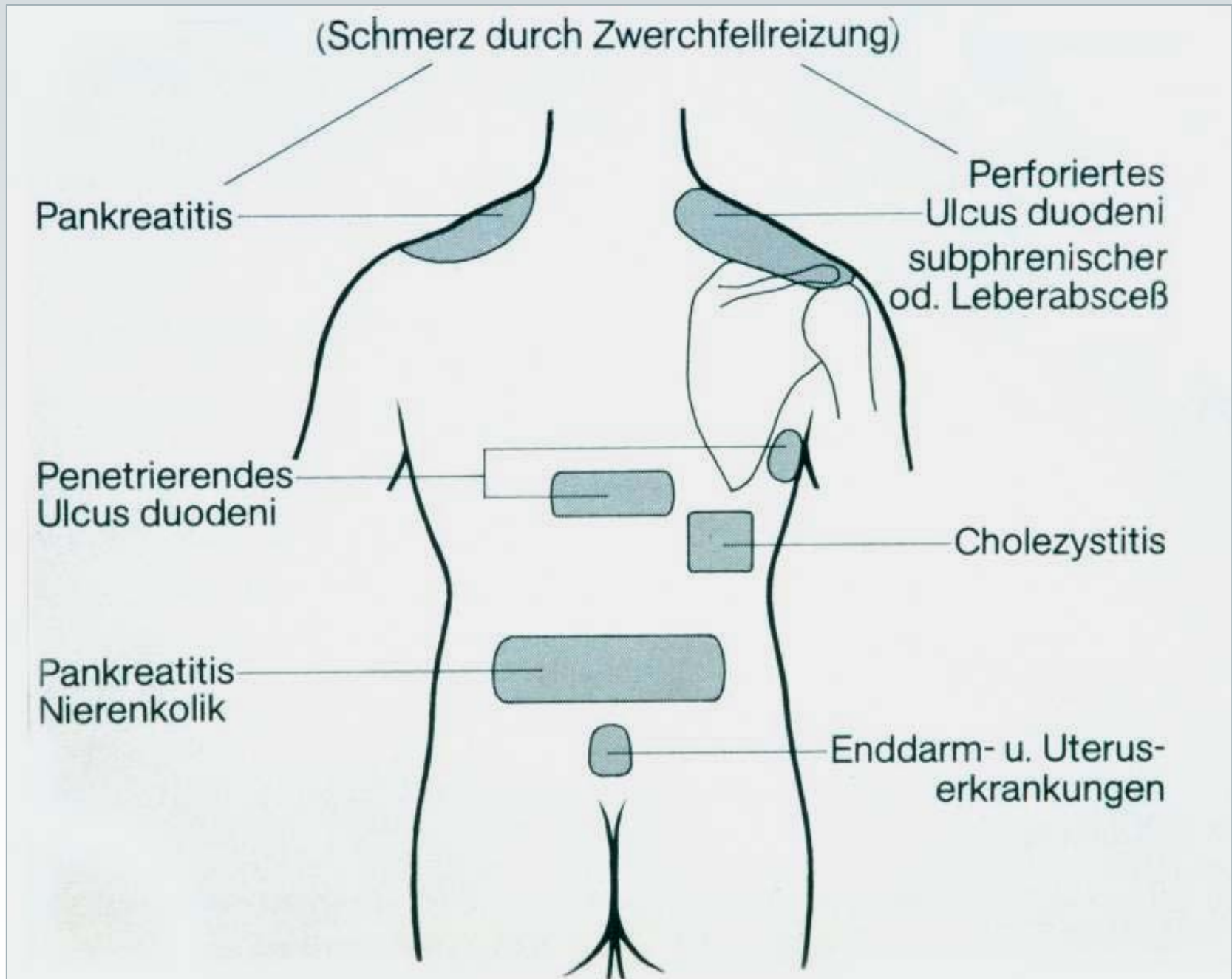
Diagnostik (1)




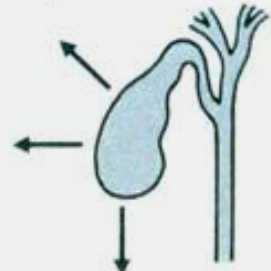



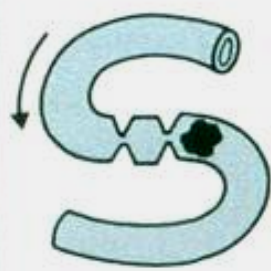




- ***Anamnese***
Beginn, Art, Lokalisation des Schmerzes
- ***Klinische Untersuchung***
Abwehrspannung? Auskultation!
- ***Labor***
Hb, Leukos, Alpha-Amylase
- ***Röntgen***
freie Luft? Spiegel?



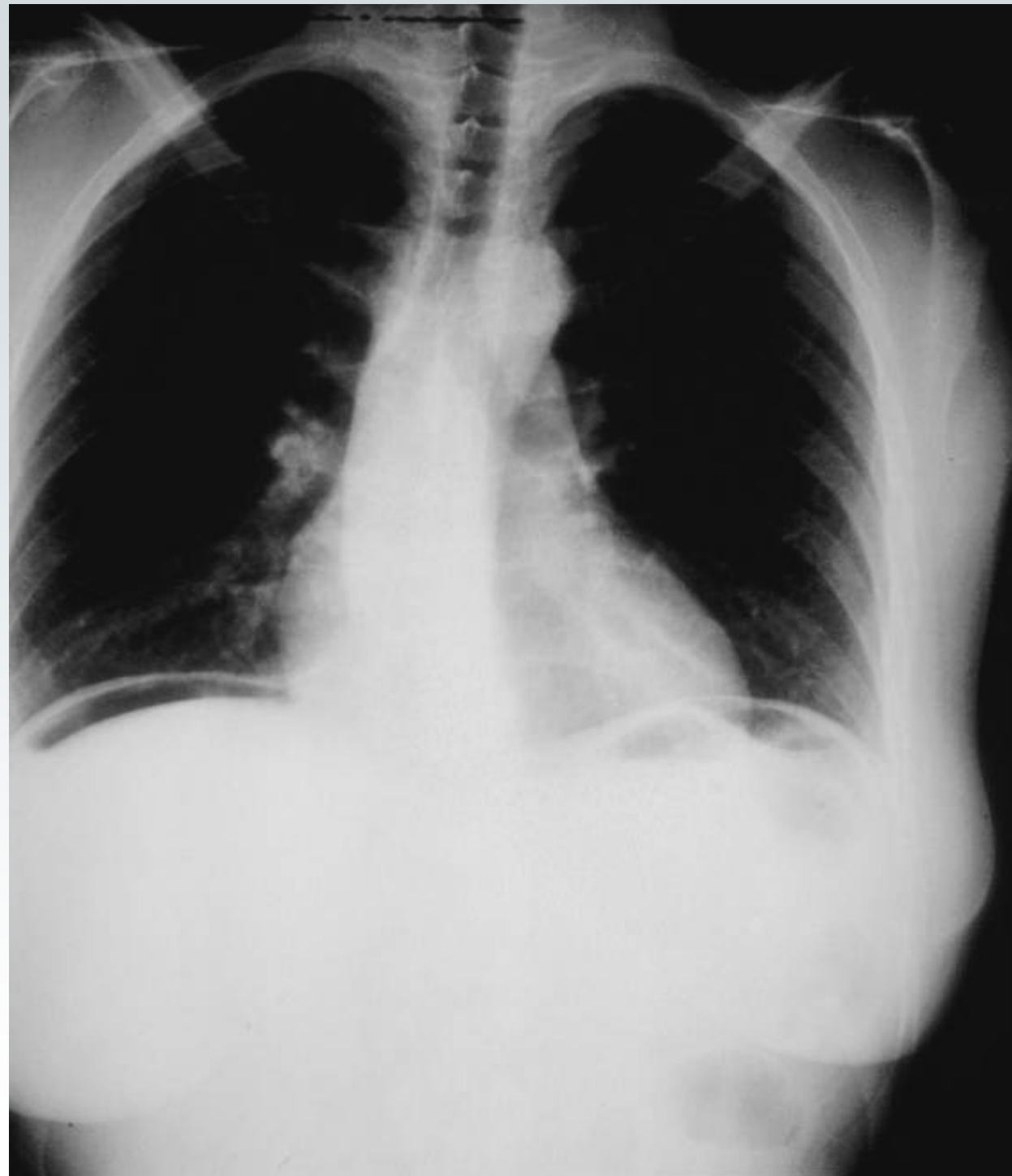





Schmerztyp	Diagnose		
 <p>Perforation</p>	<p>Ulcusperforation</p> 	<p>Mesenterialinfarkt</p> 	<p>Gallenblasenperforation</p> 
 <p>Kolik</p>	<p>Gallenkolik</p> 	<p>Uretersteinkolik</p> 	<p>Ileus</p> 
 <p>Entzündung</p>	<p>Appendicitis</p> 	<p>Pankreatitis</p> 	<p>Cholecystitis</p> 



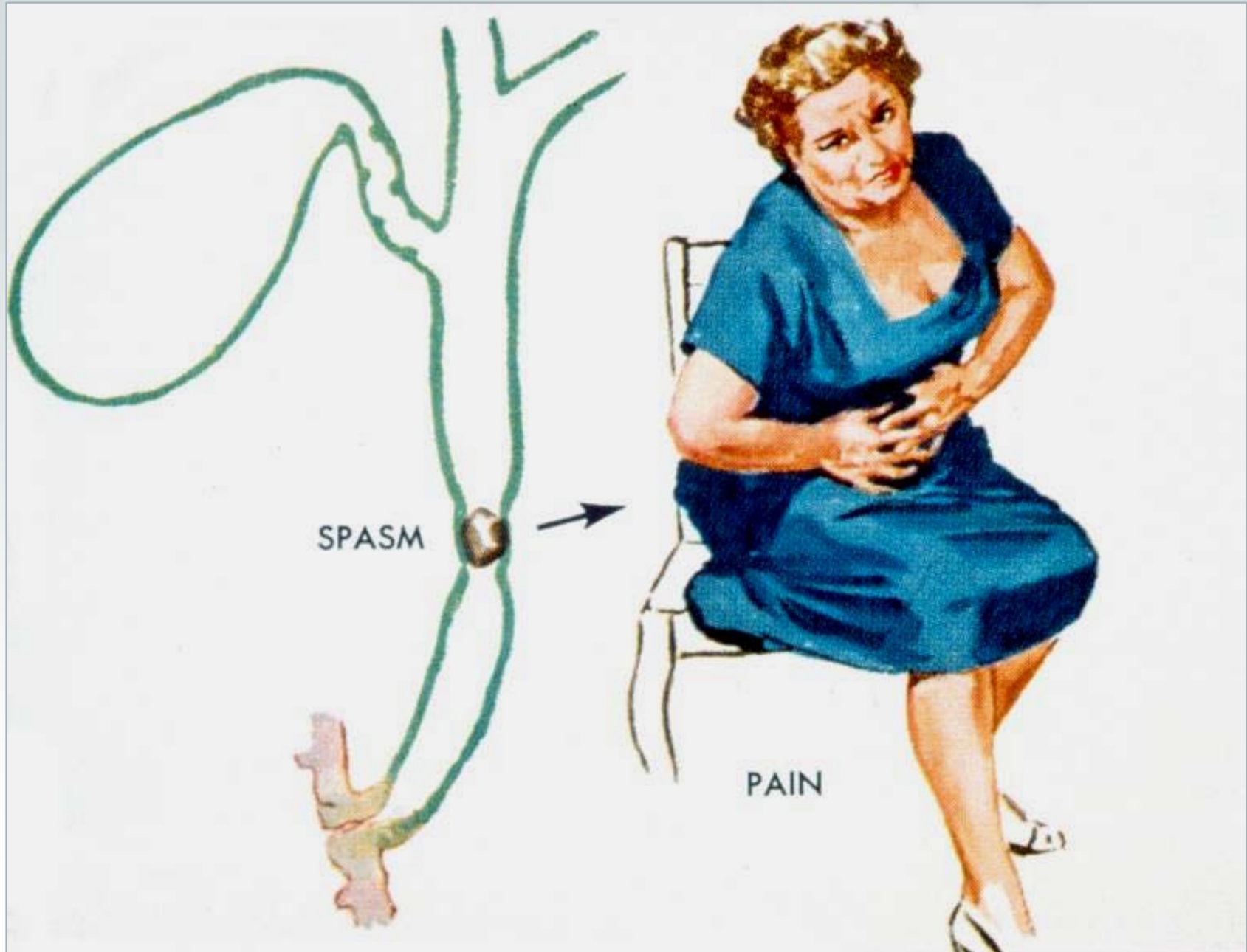


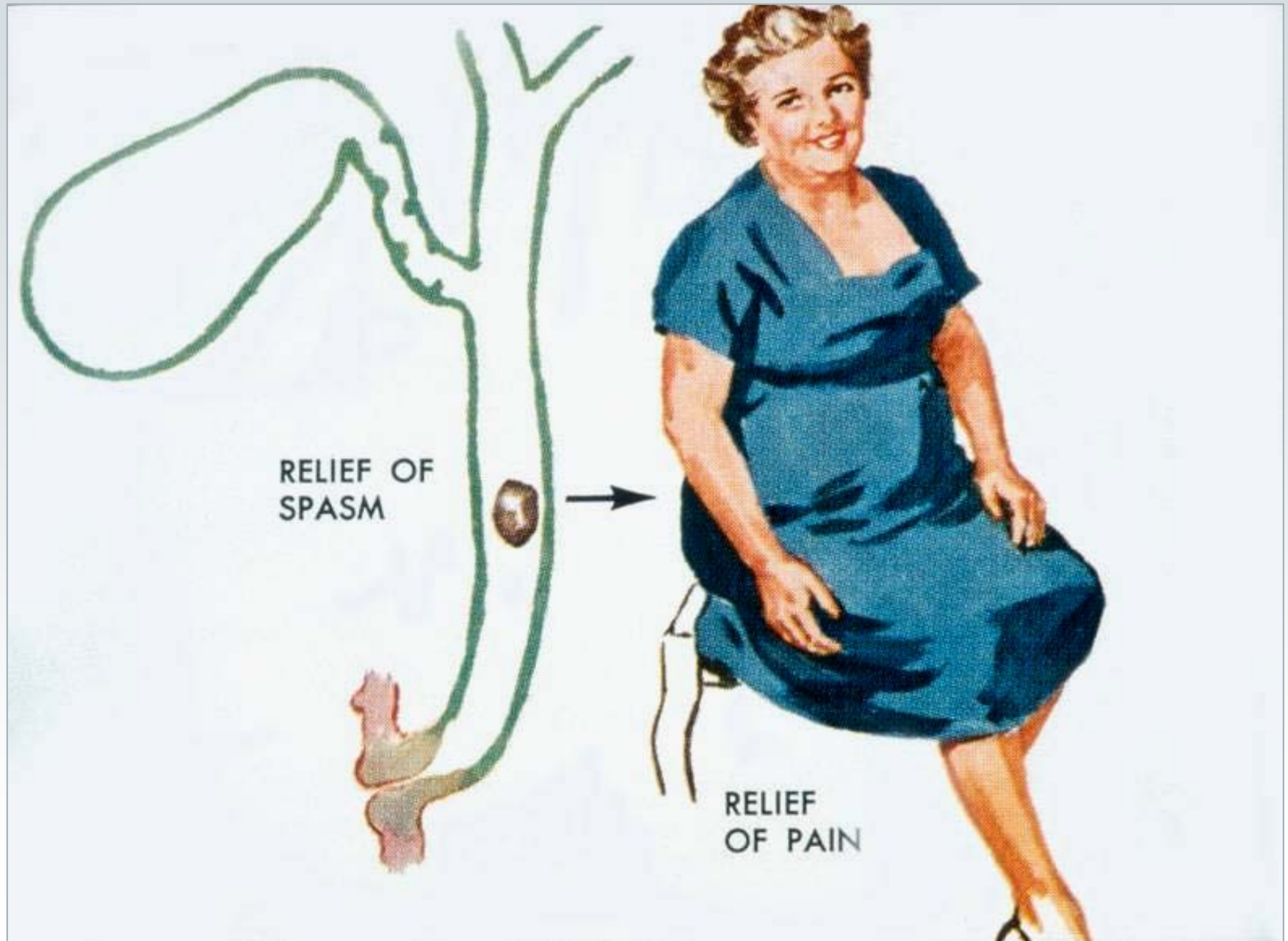
Akutes Abdomen

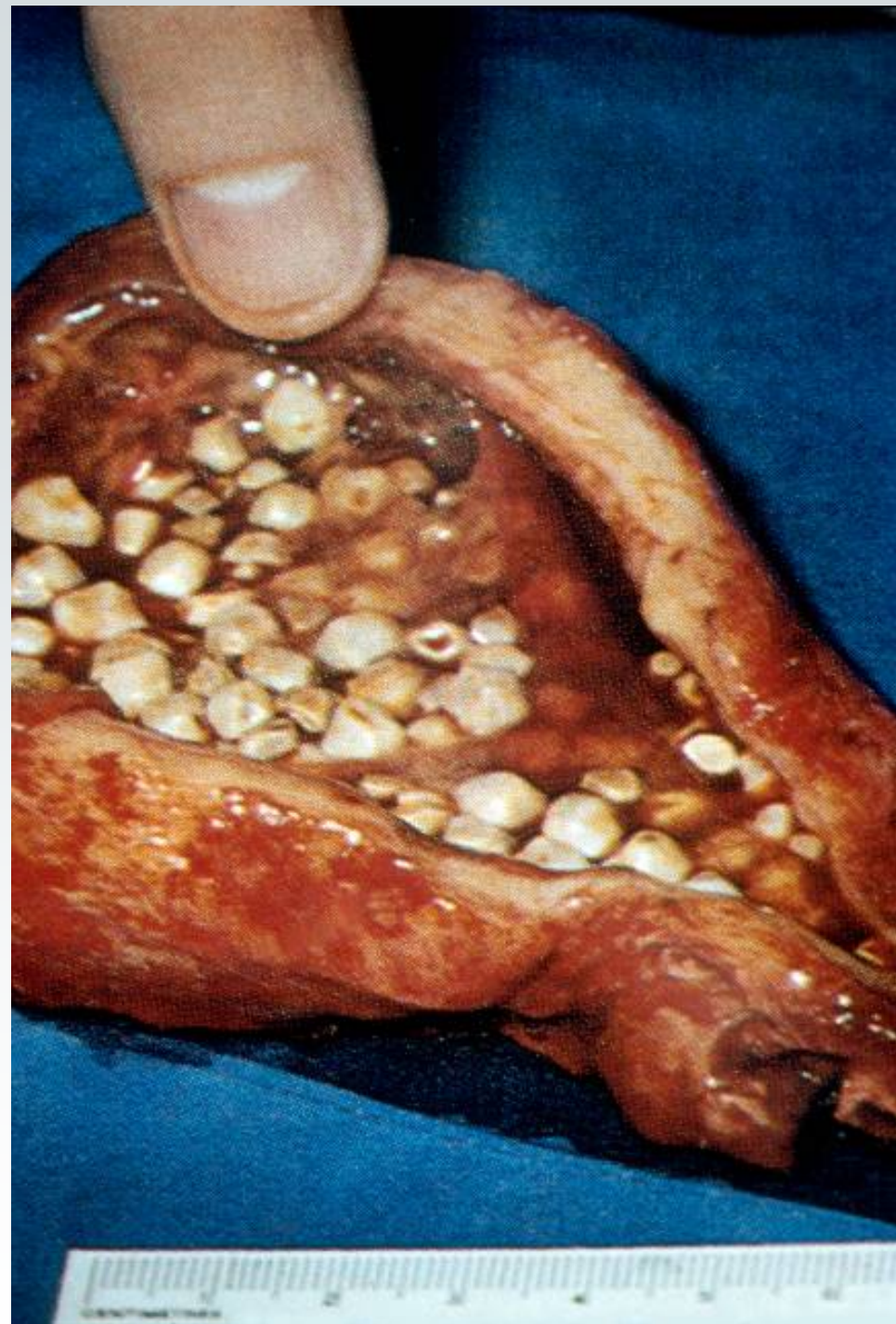Diagnostik (2)

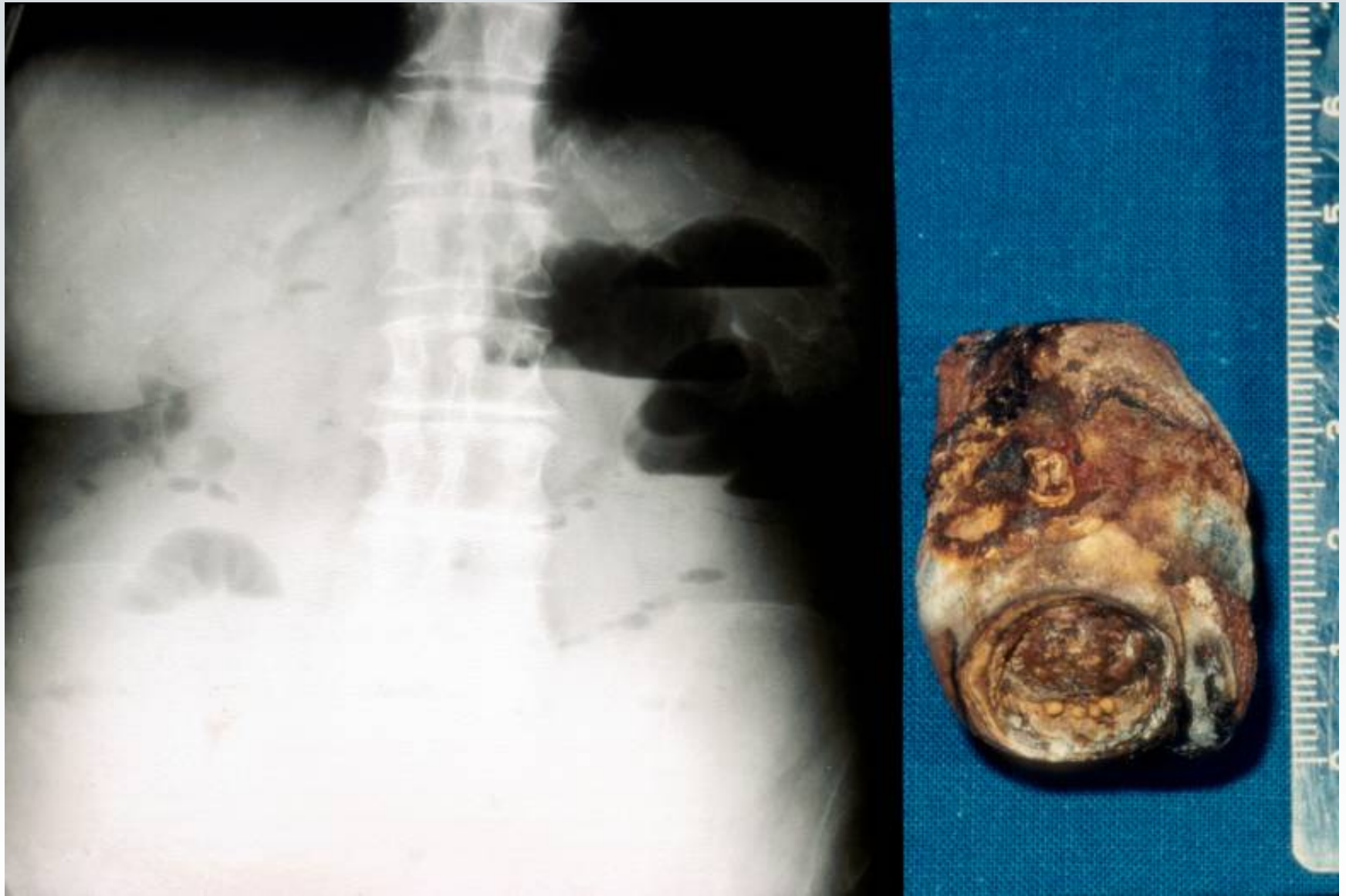
- ***Ultraschall***
freie Flüssigkeit, Abzeß, Kokarde?
Cholecystitis? Pankreatitis?
- ***CT***
Parenchymläsionen? Pankreatitis?
- ***Angiographie***
Mesenterialverschuß?







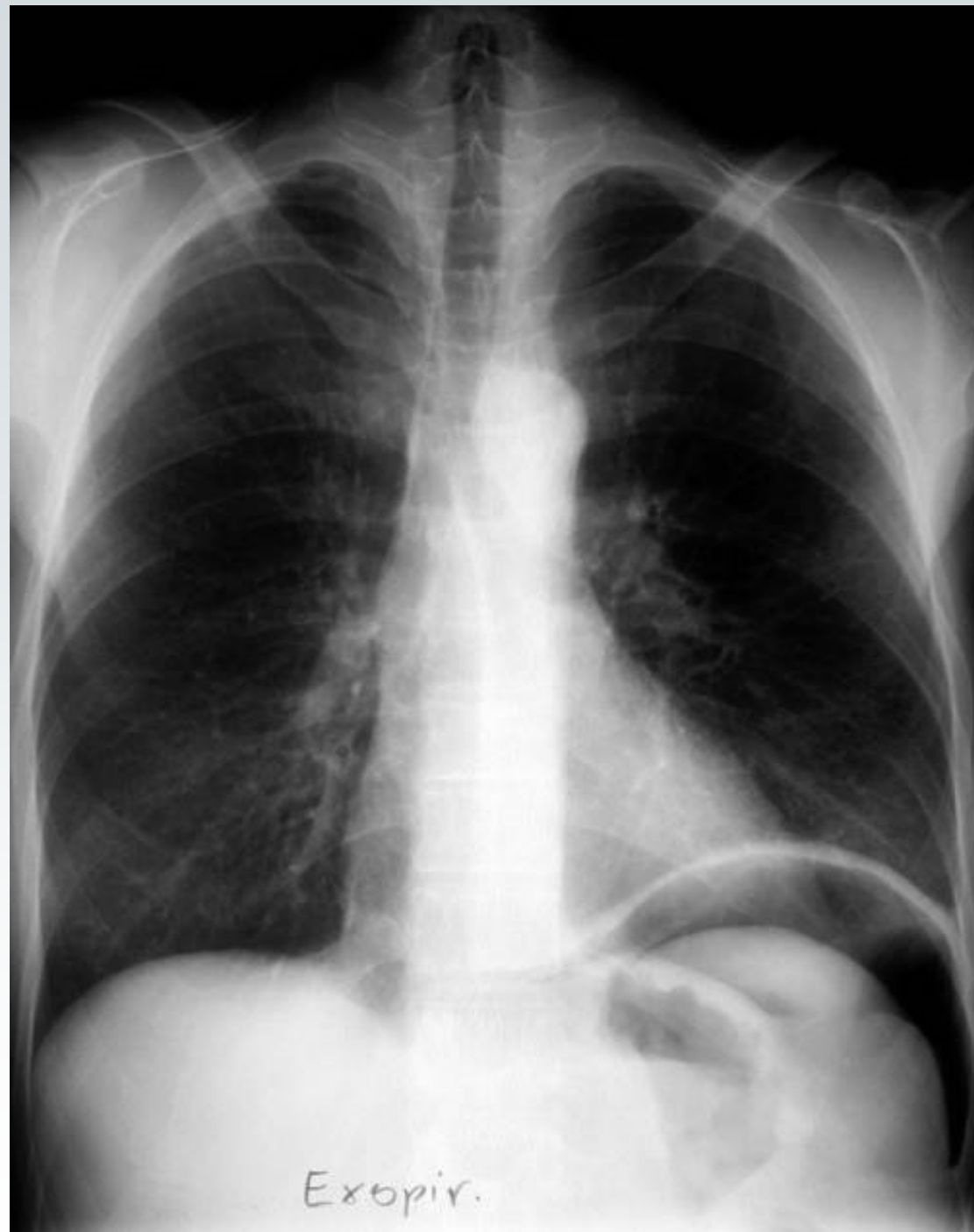


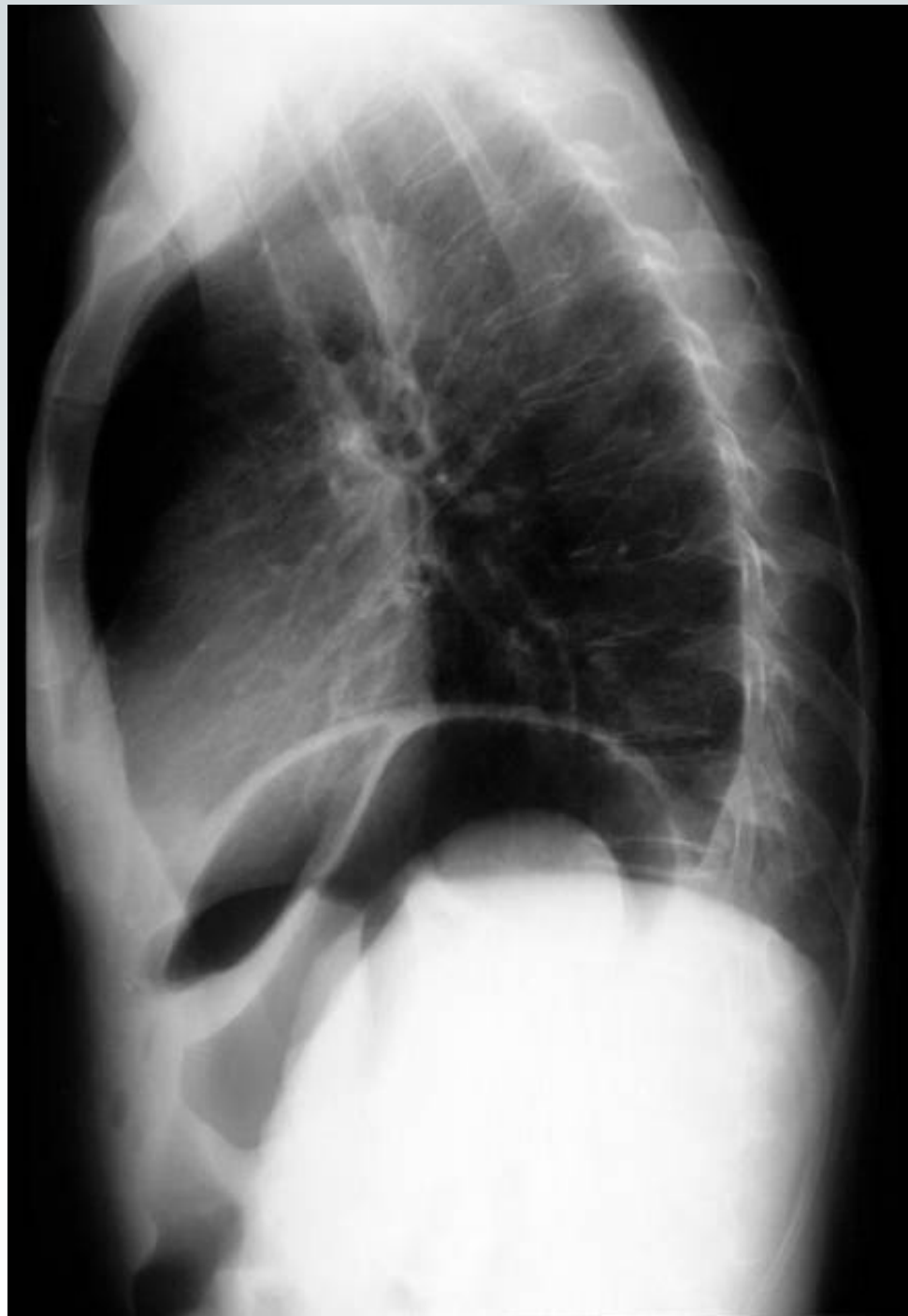

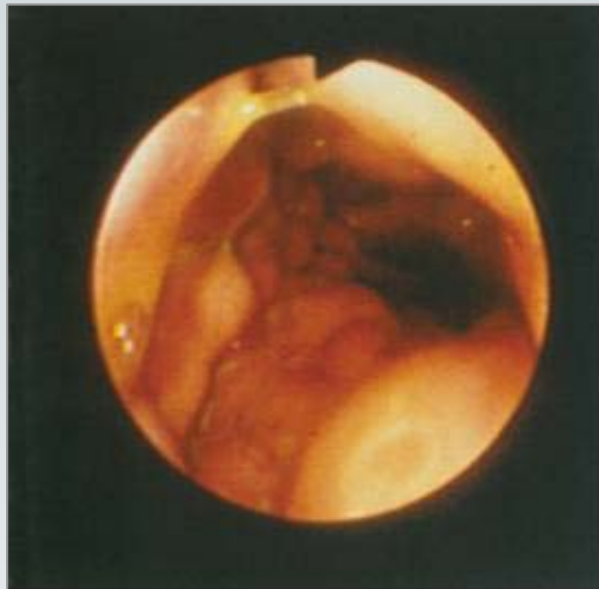Akutes Abdomen

**gastrointestinale
Perforation**

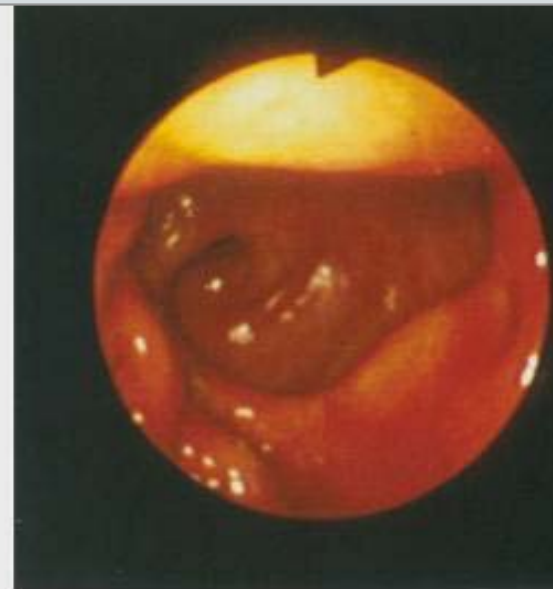




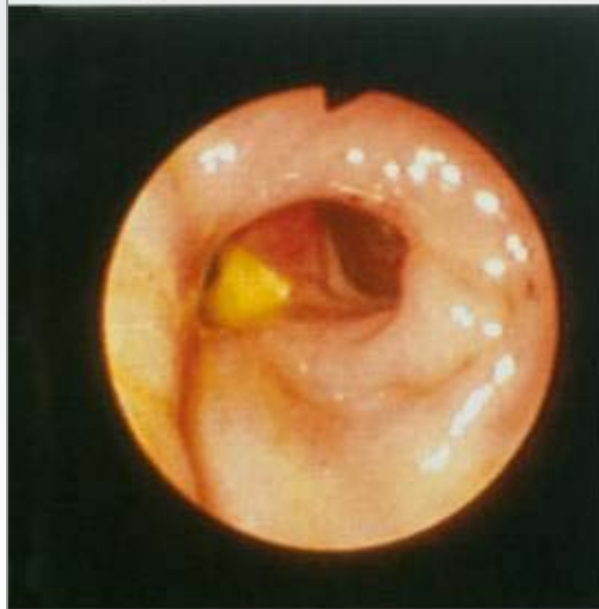



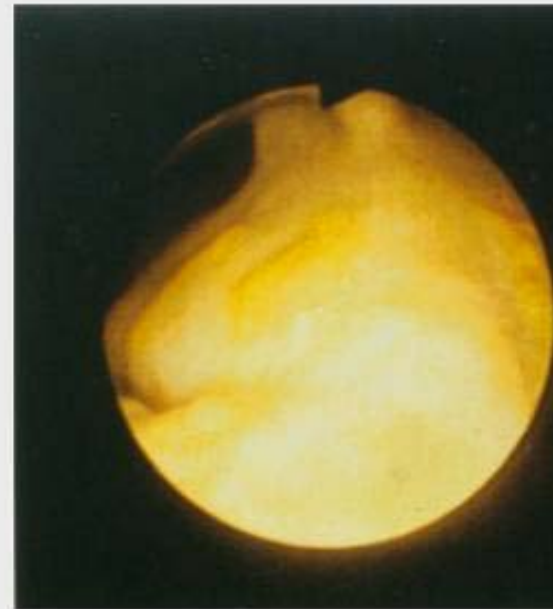Magen



Anastomose



Anastomose



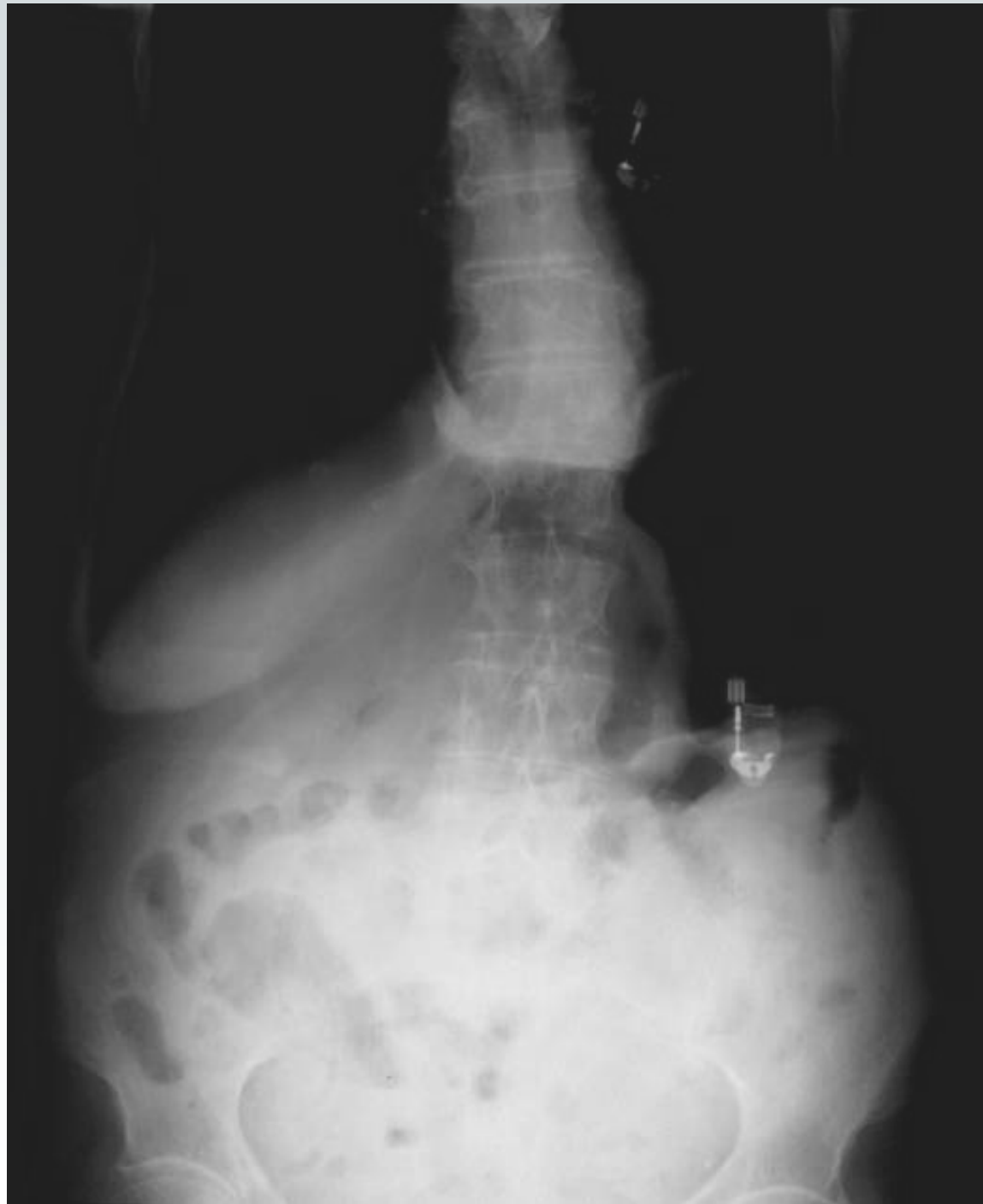Anastomose

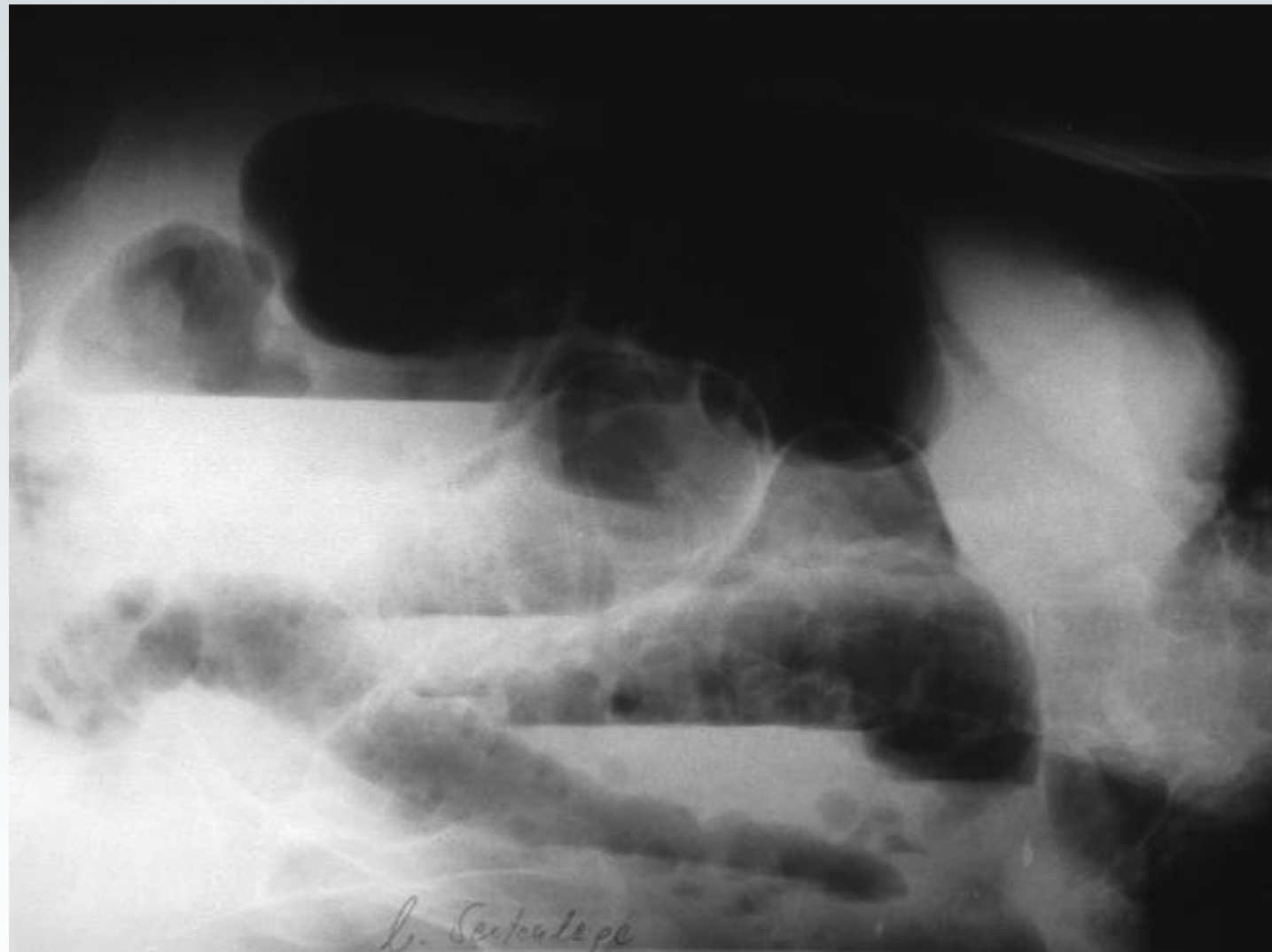


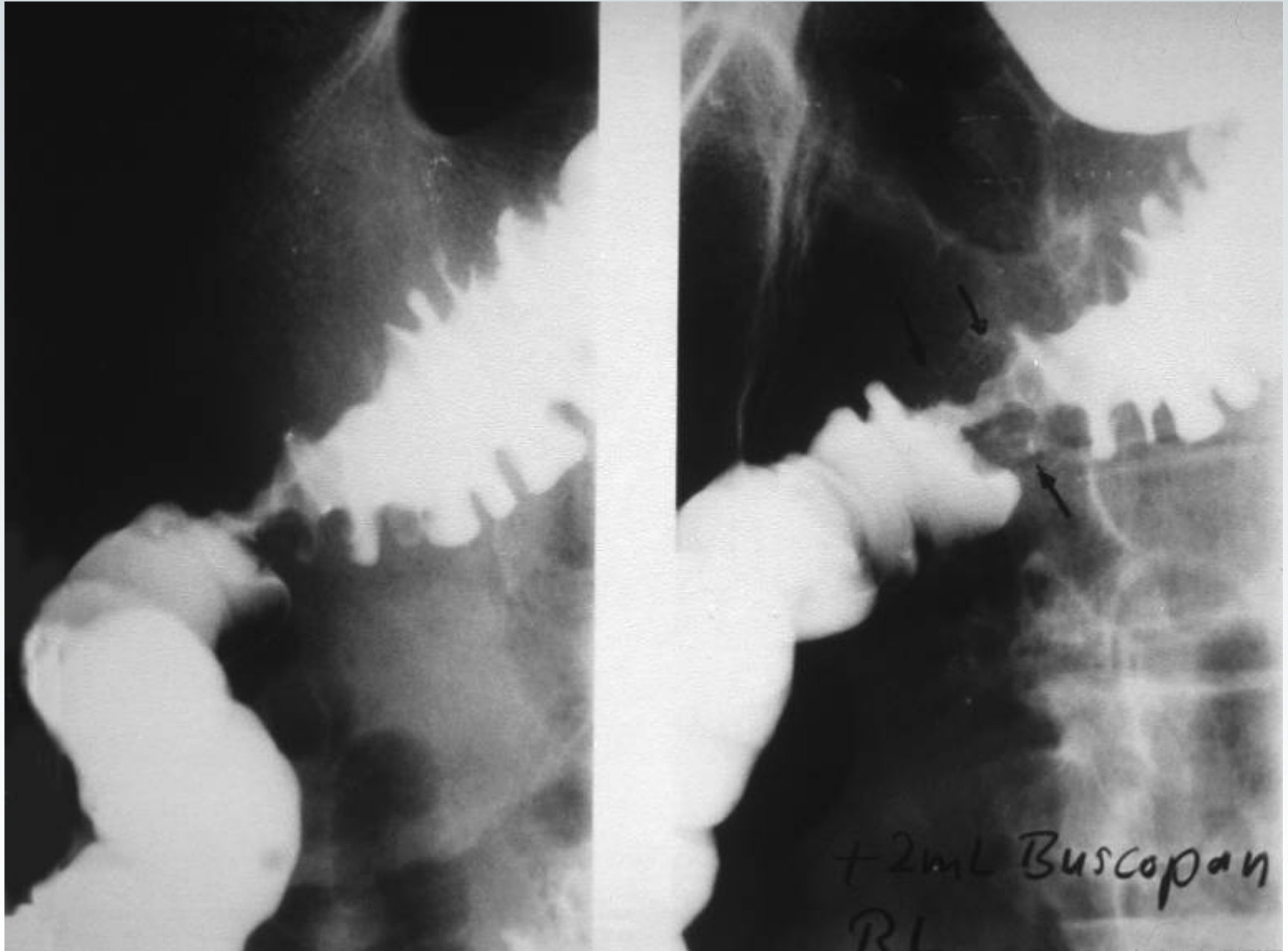
Akutes Abdomen

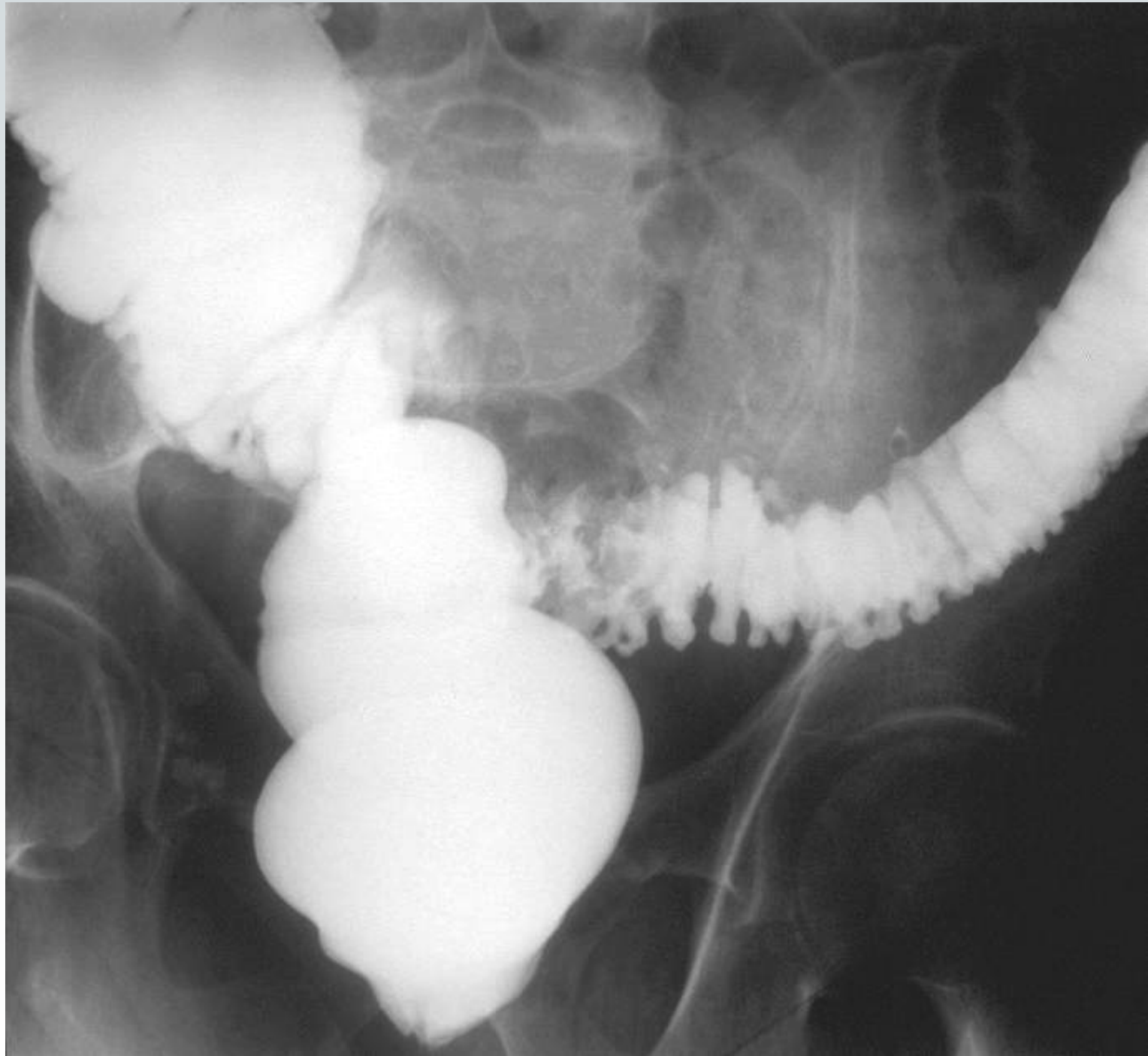
Sigma- divertikulitis

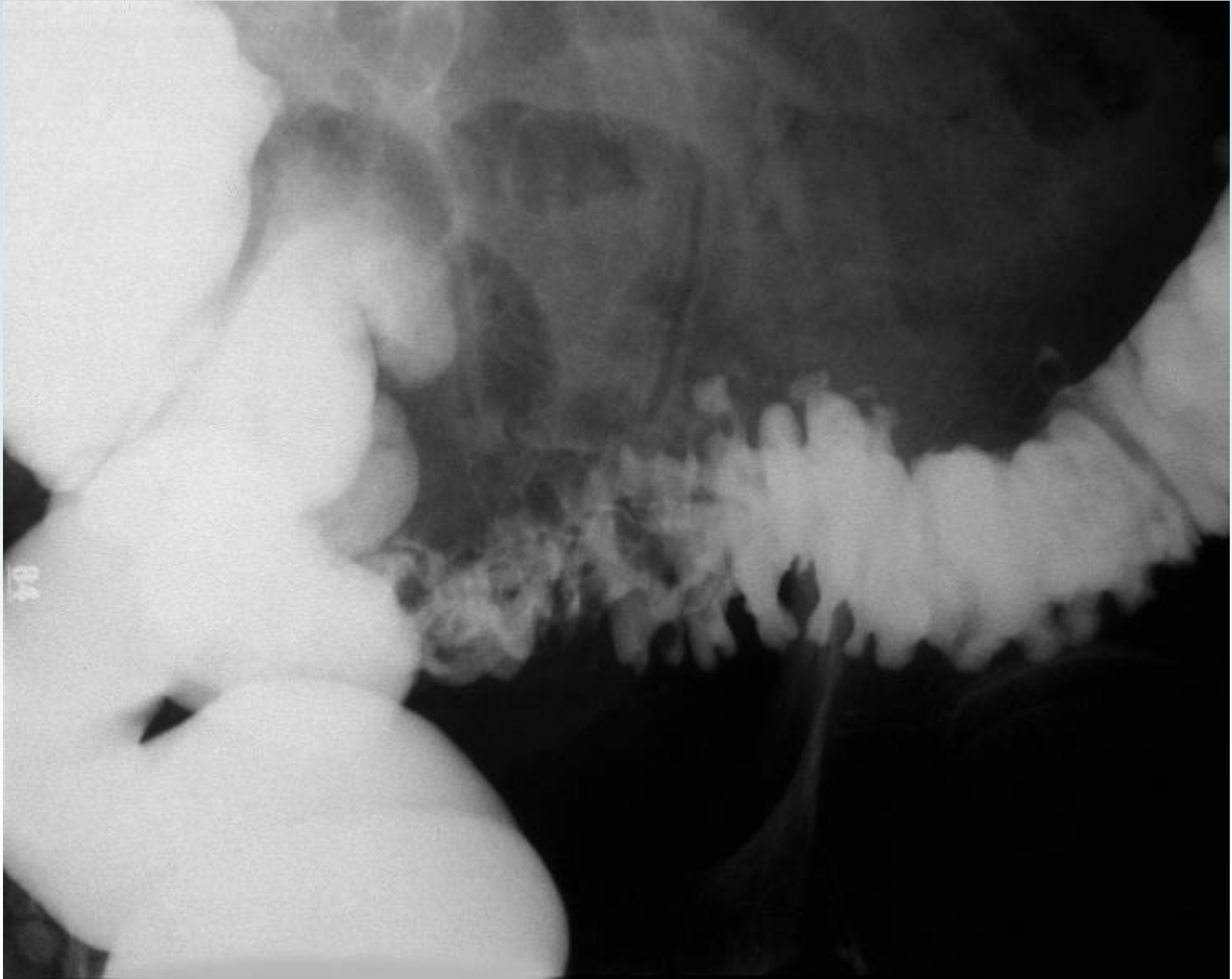


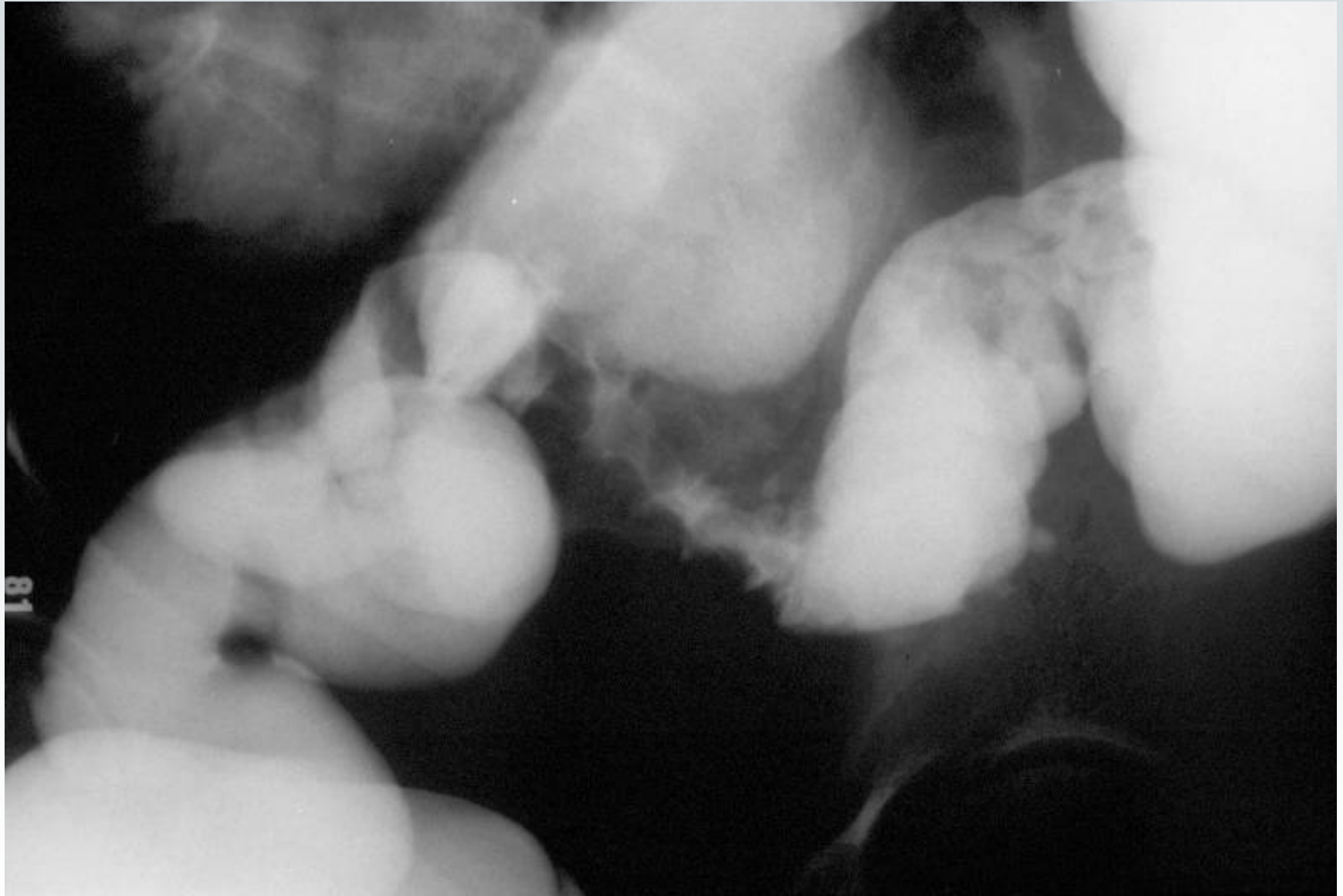

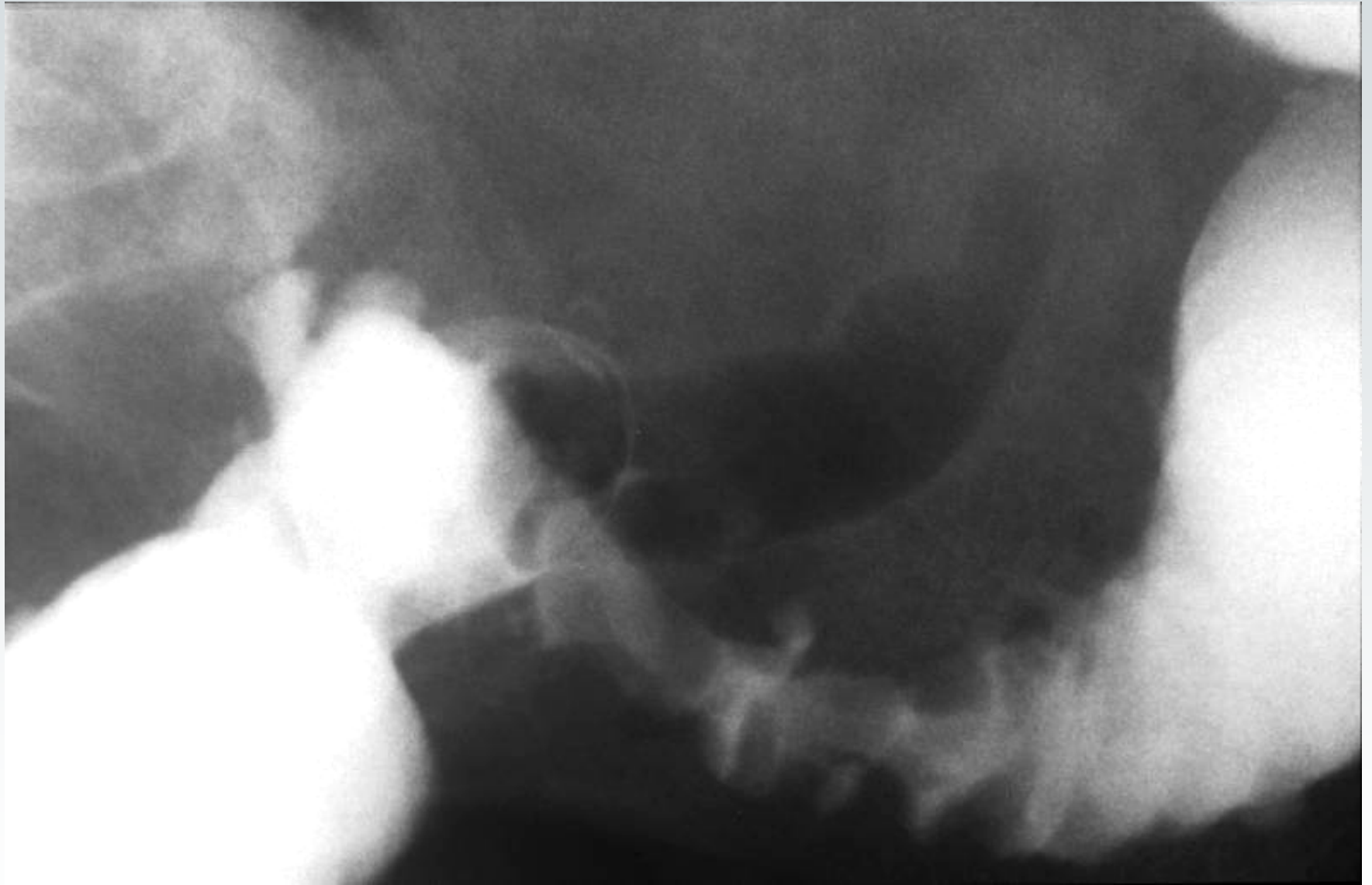


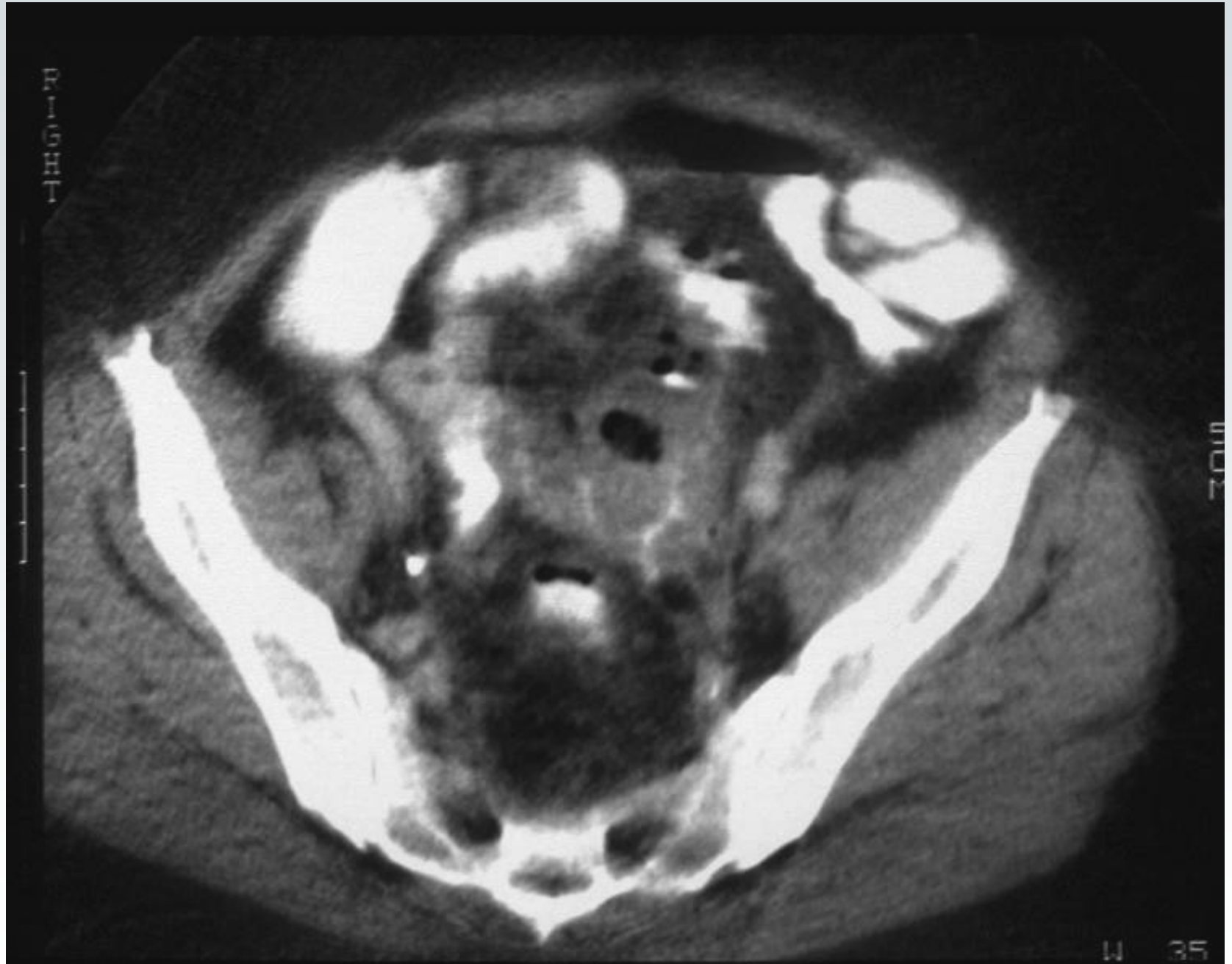



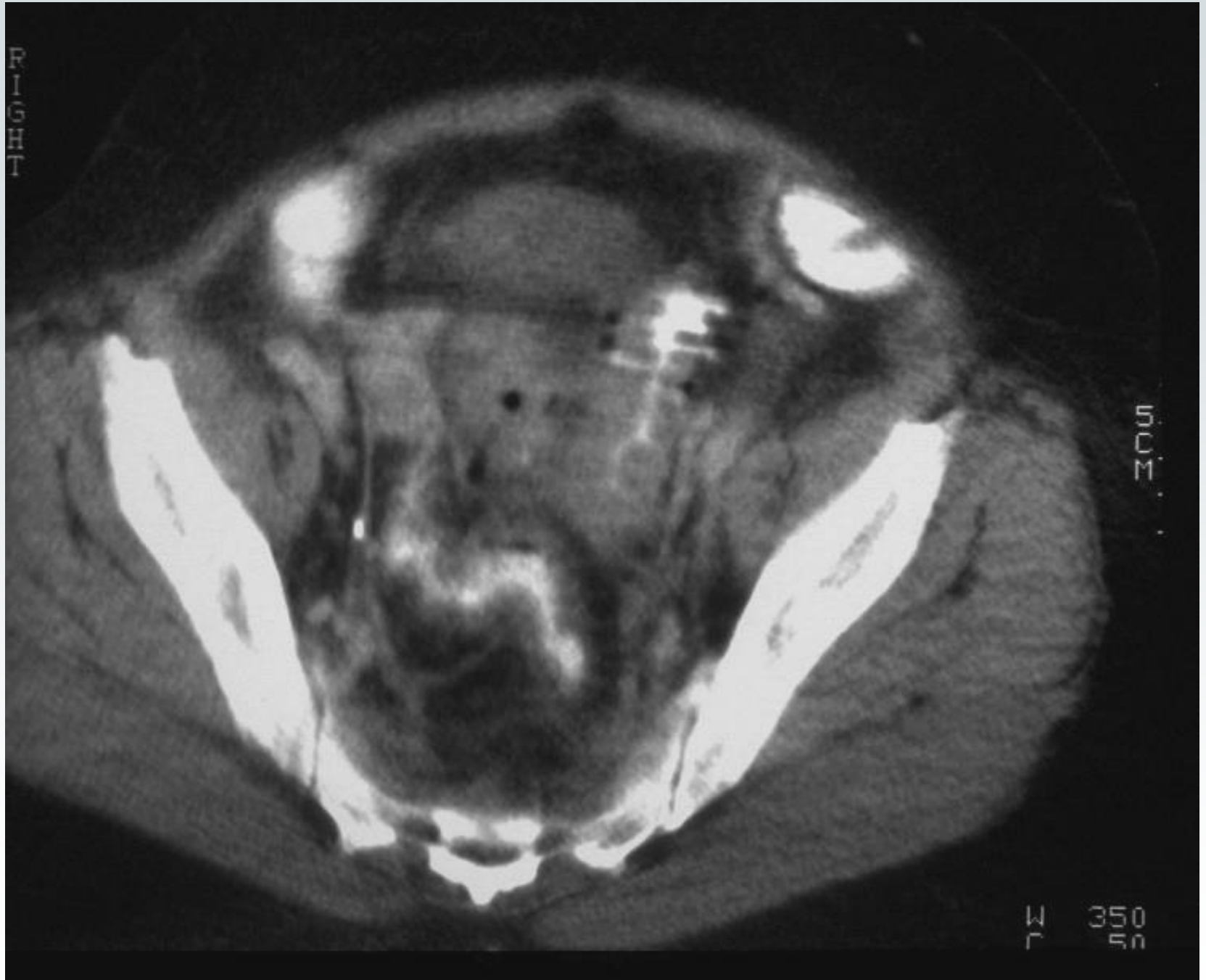


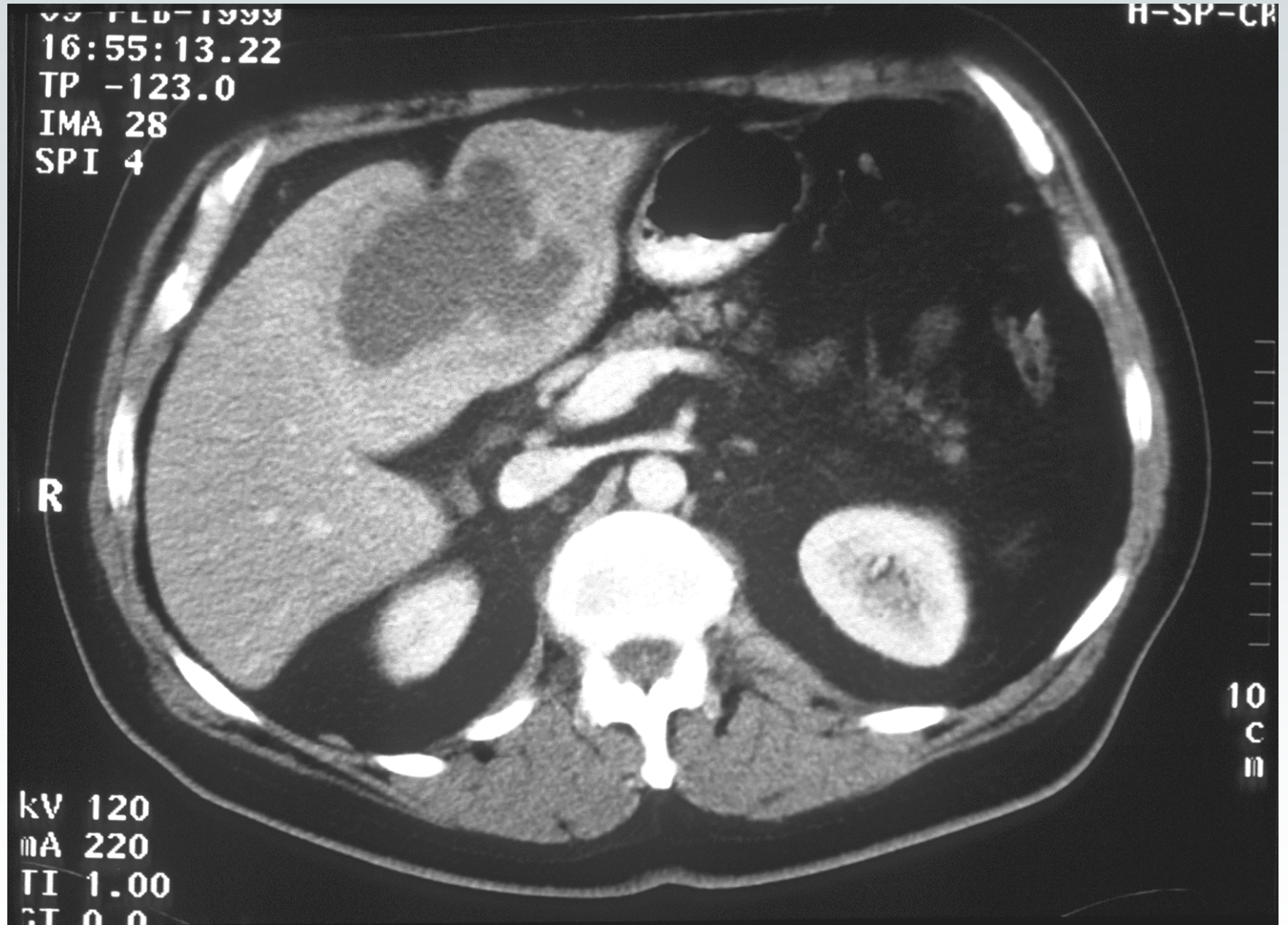








Akutes Abdomen



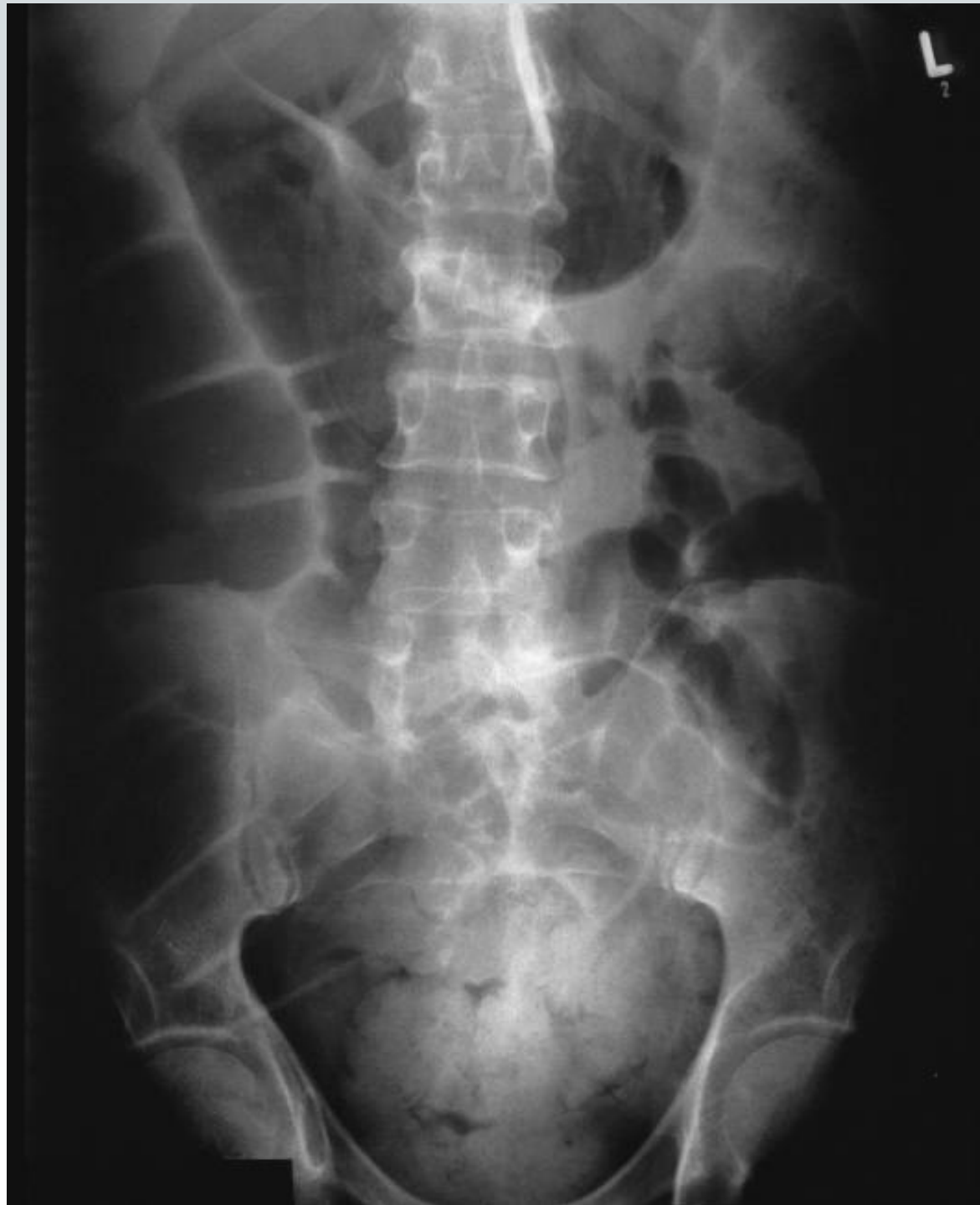Schneider 11.10.04

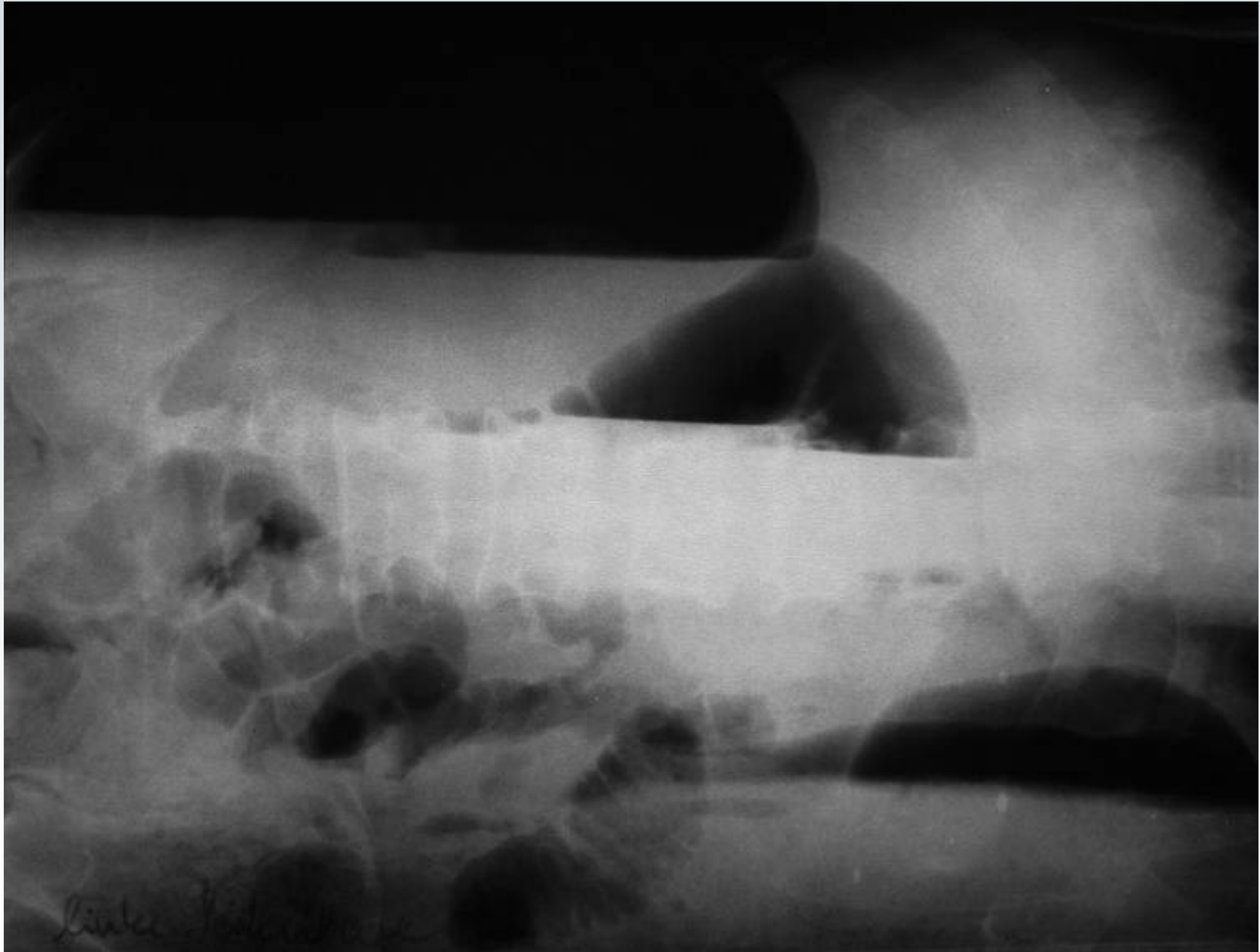Akutes Abdomen

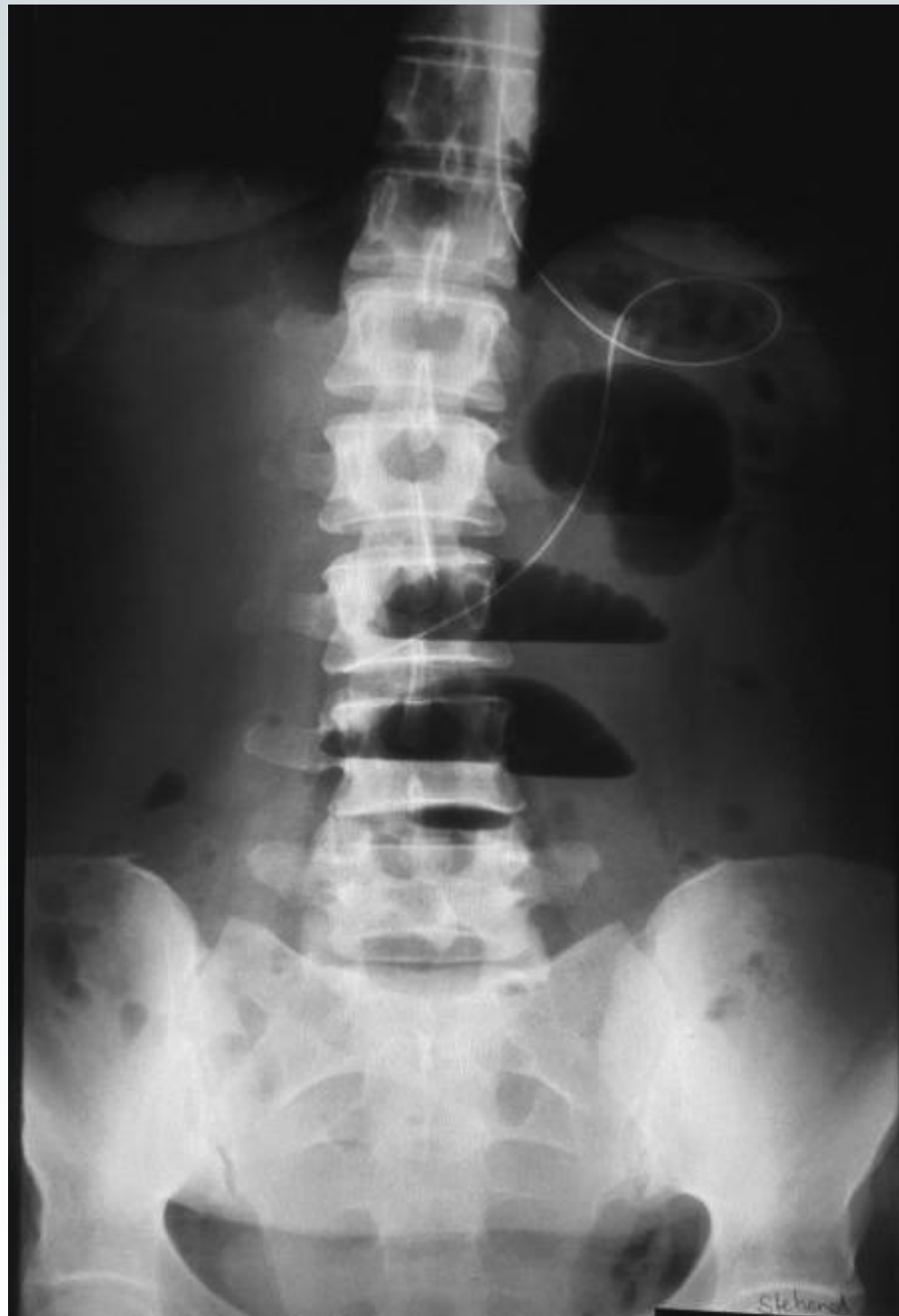Ileus

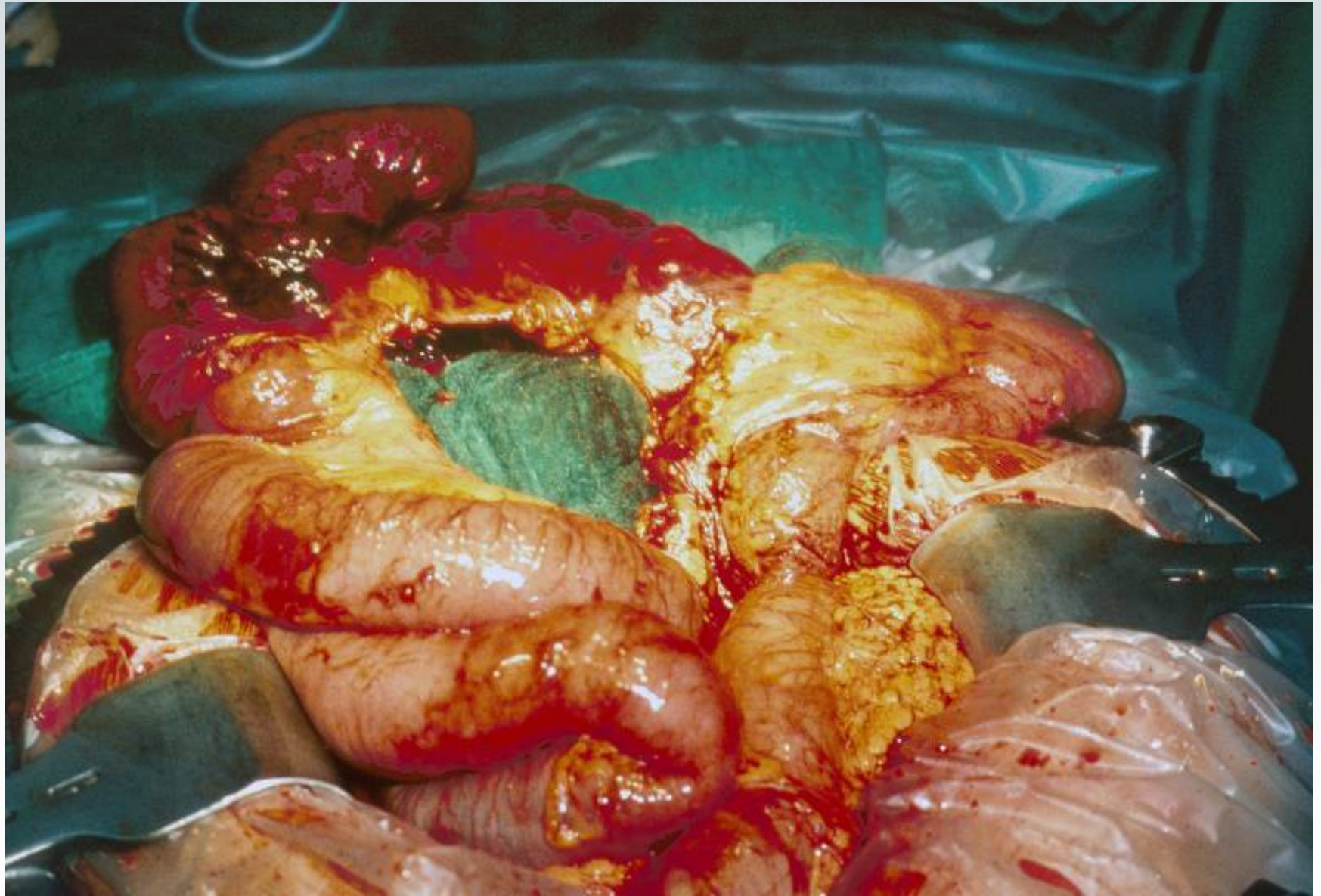


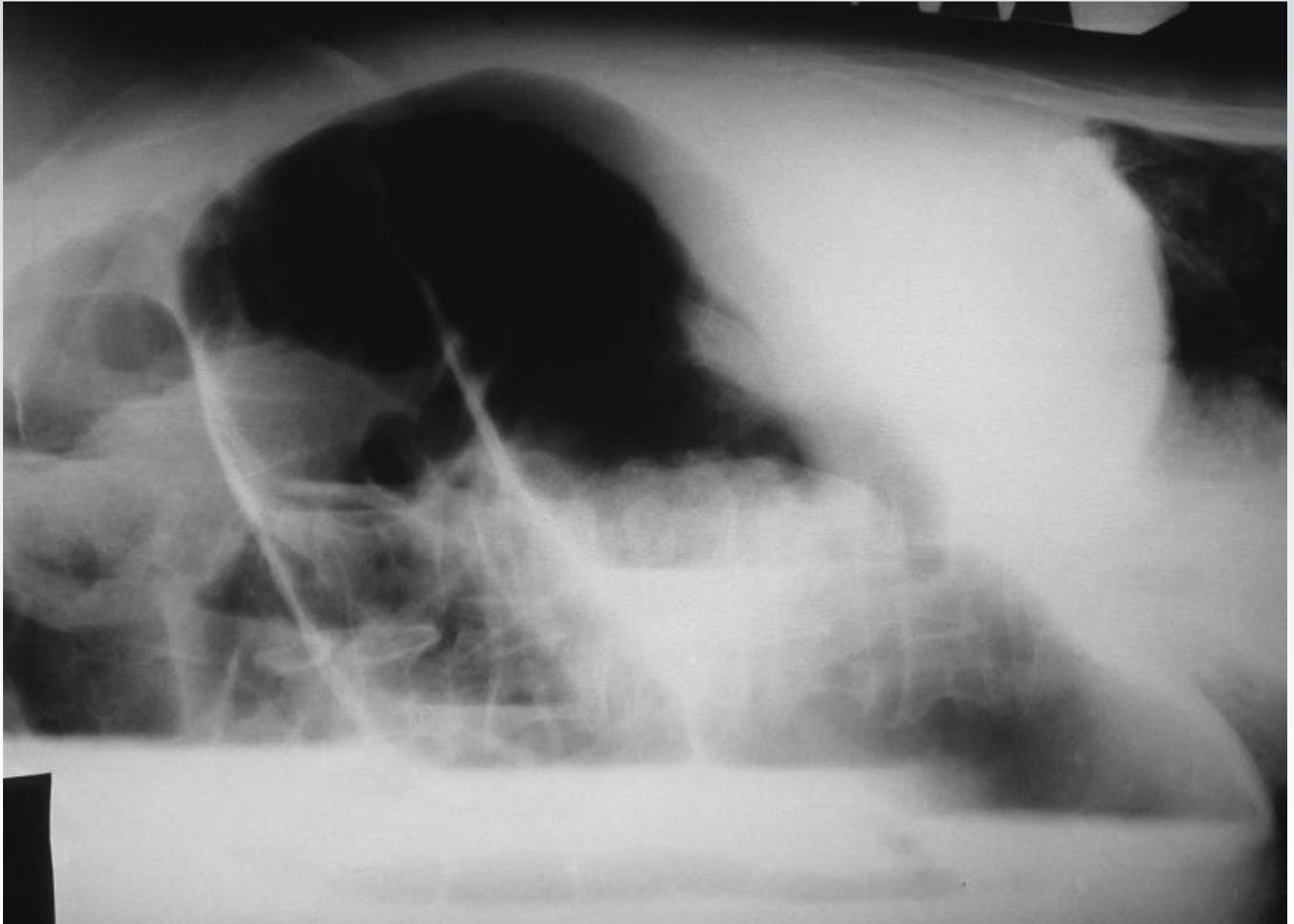
Akutes Abdomen

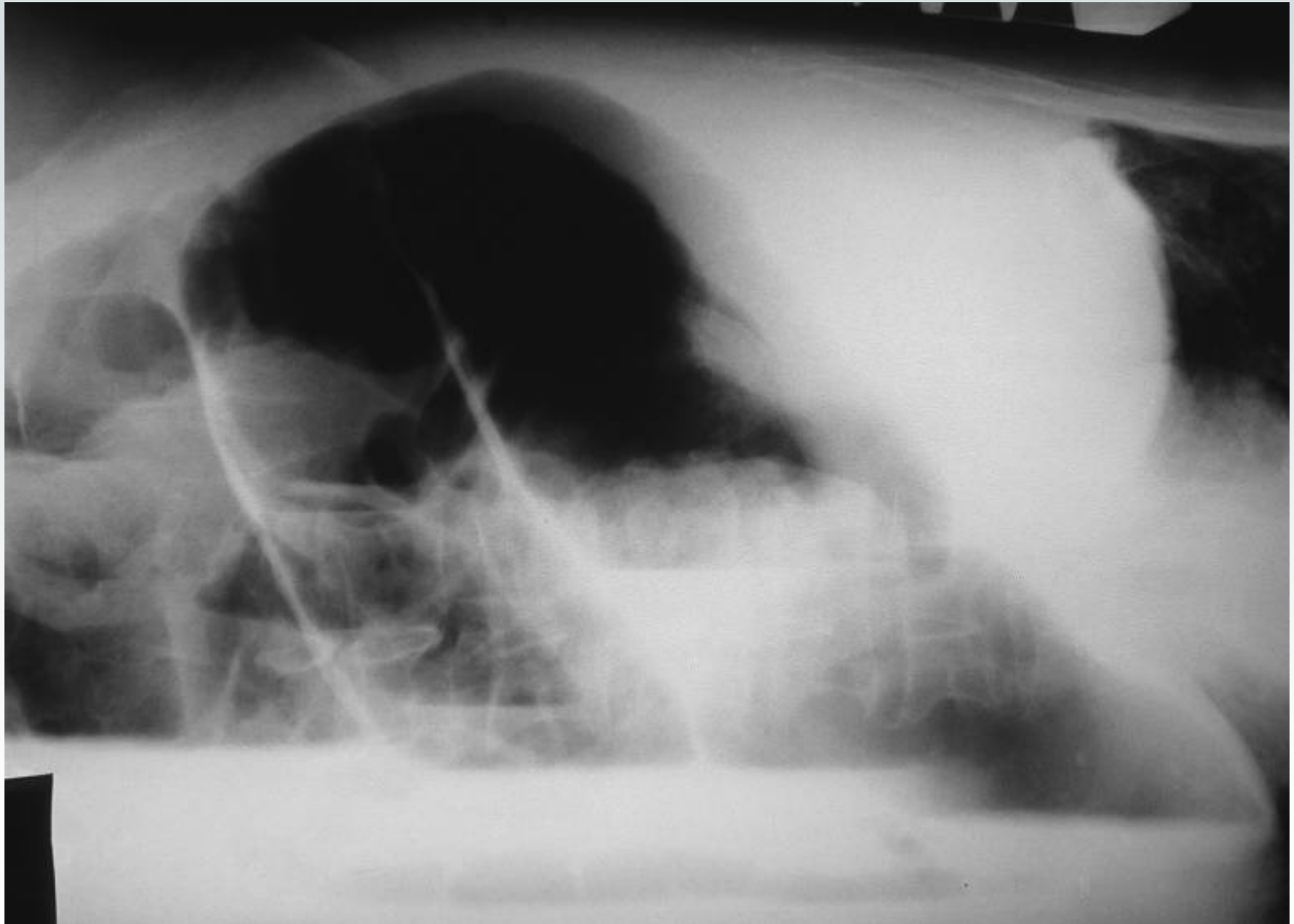


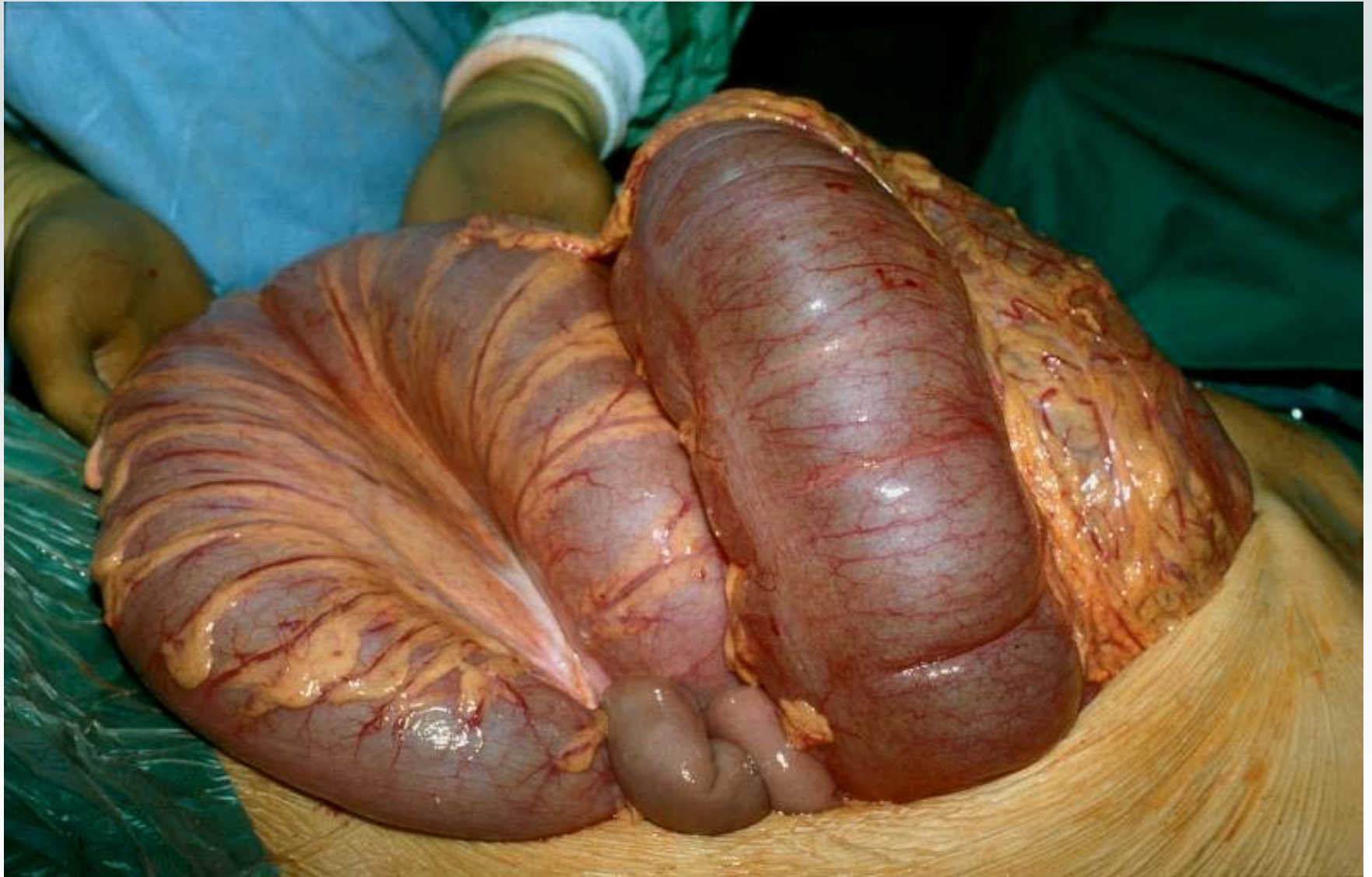

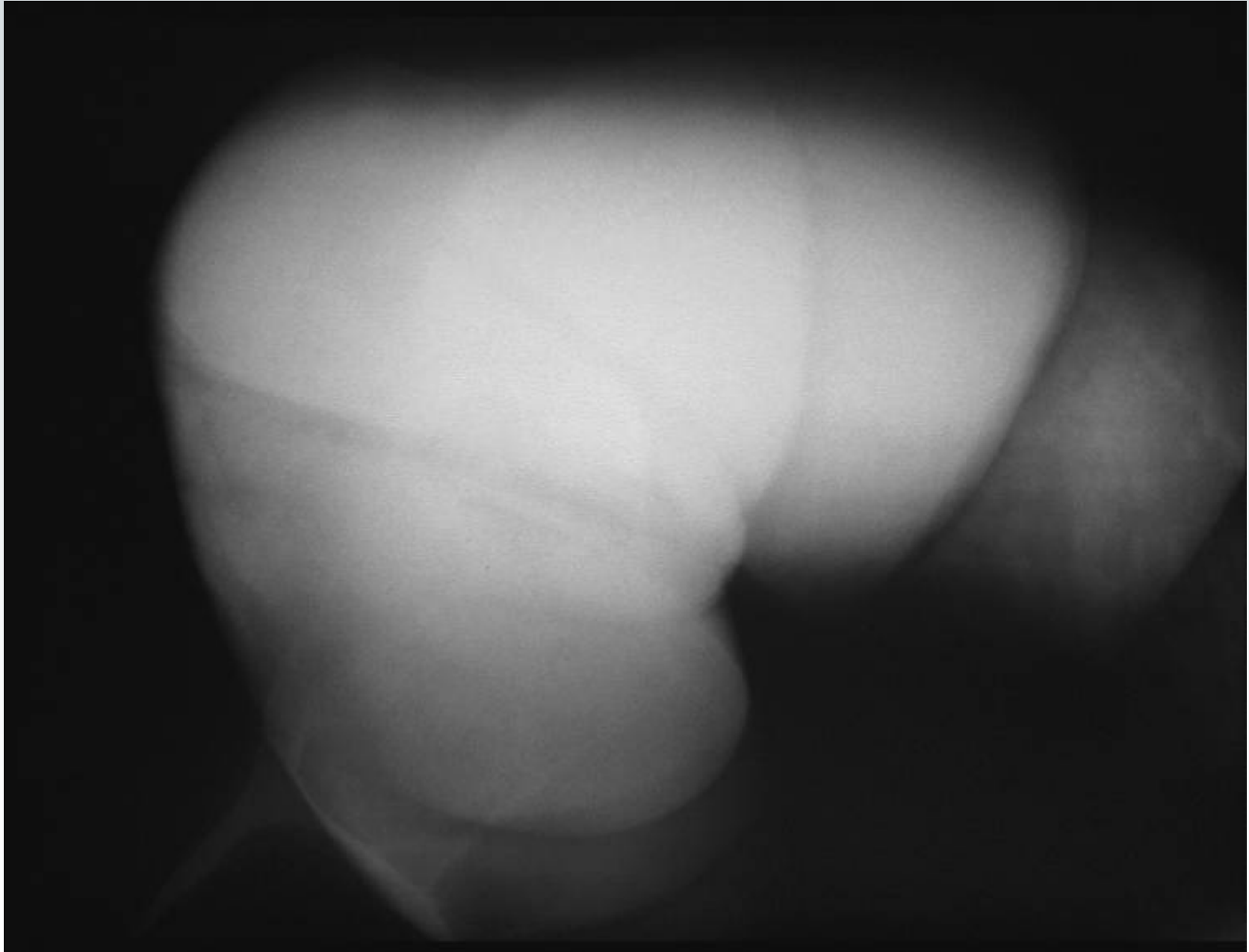


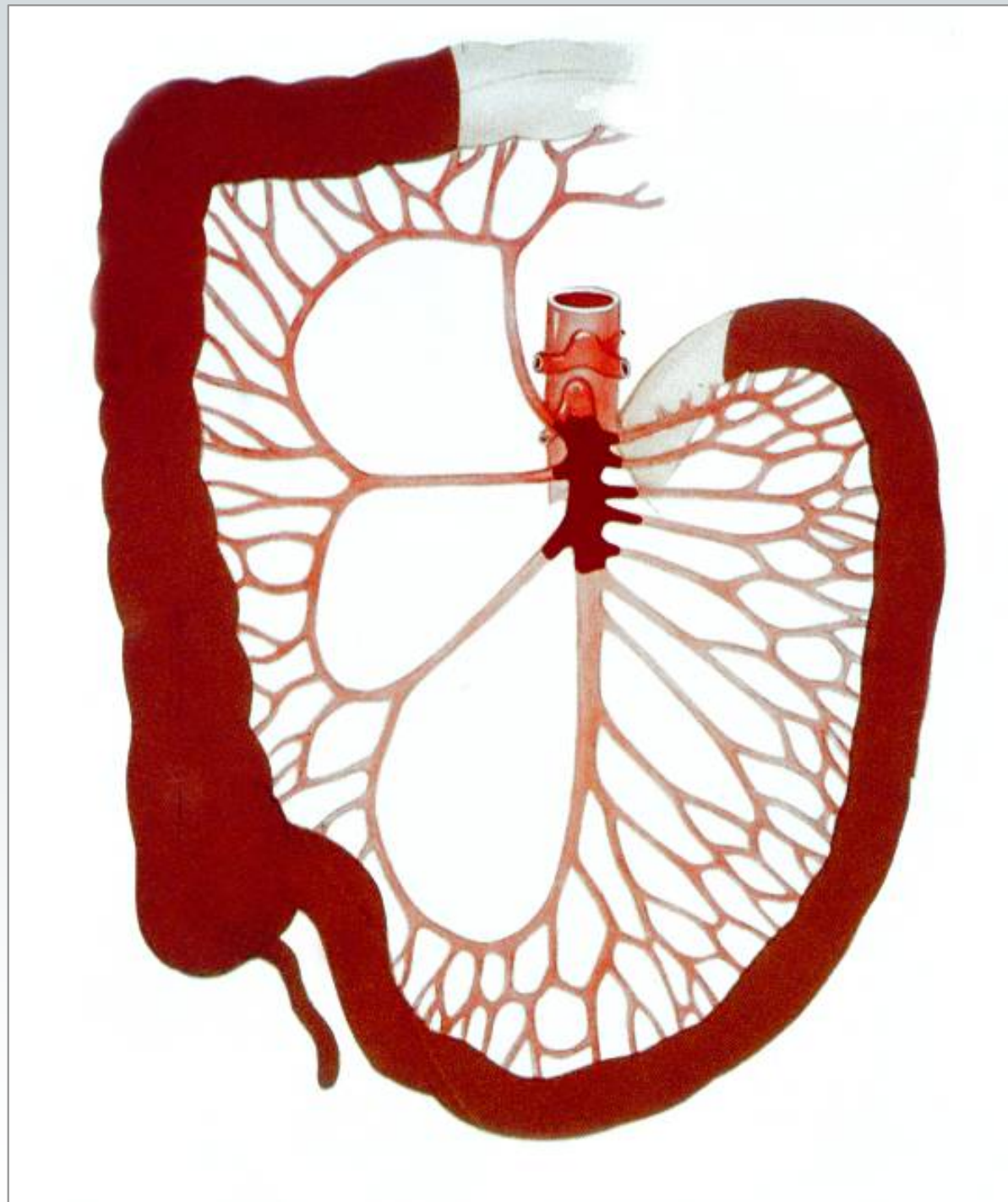









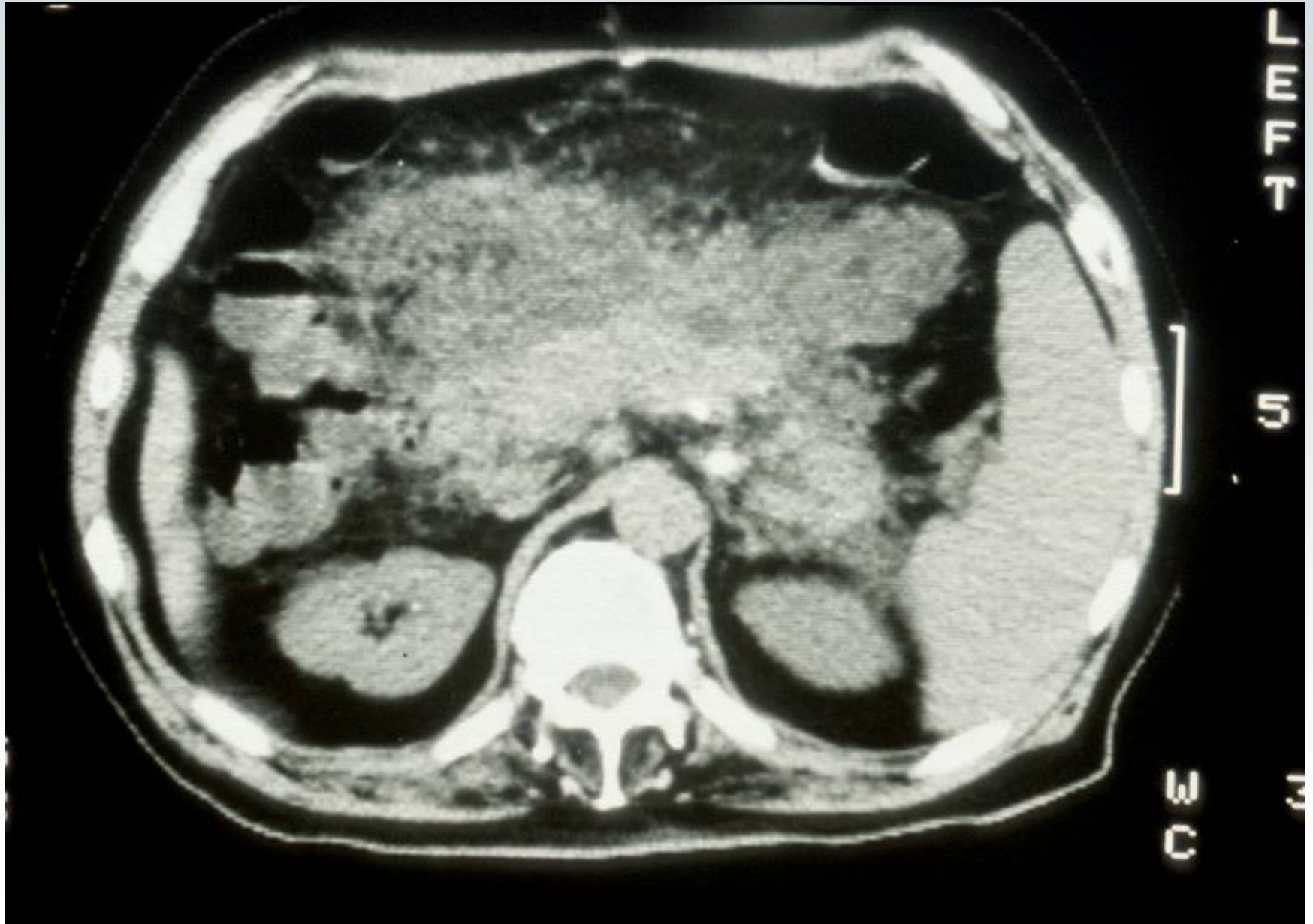


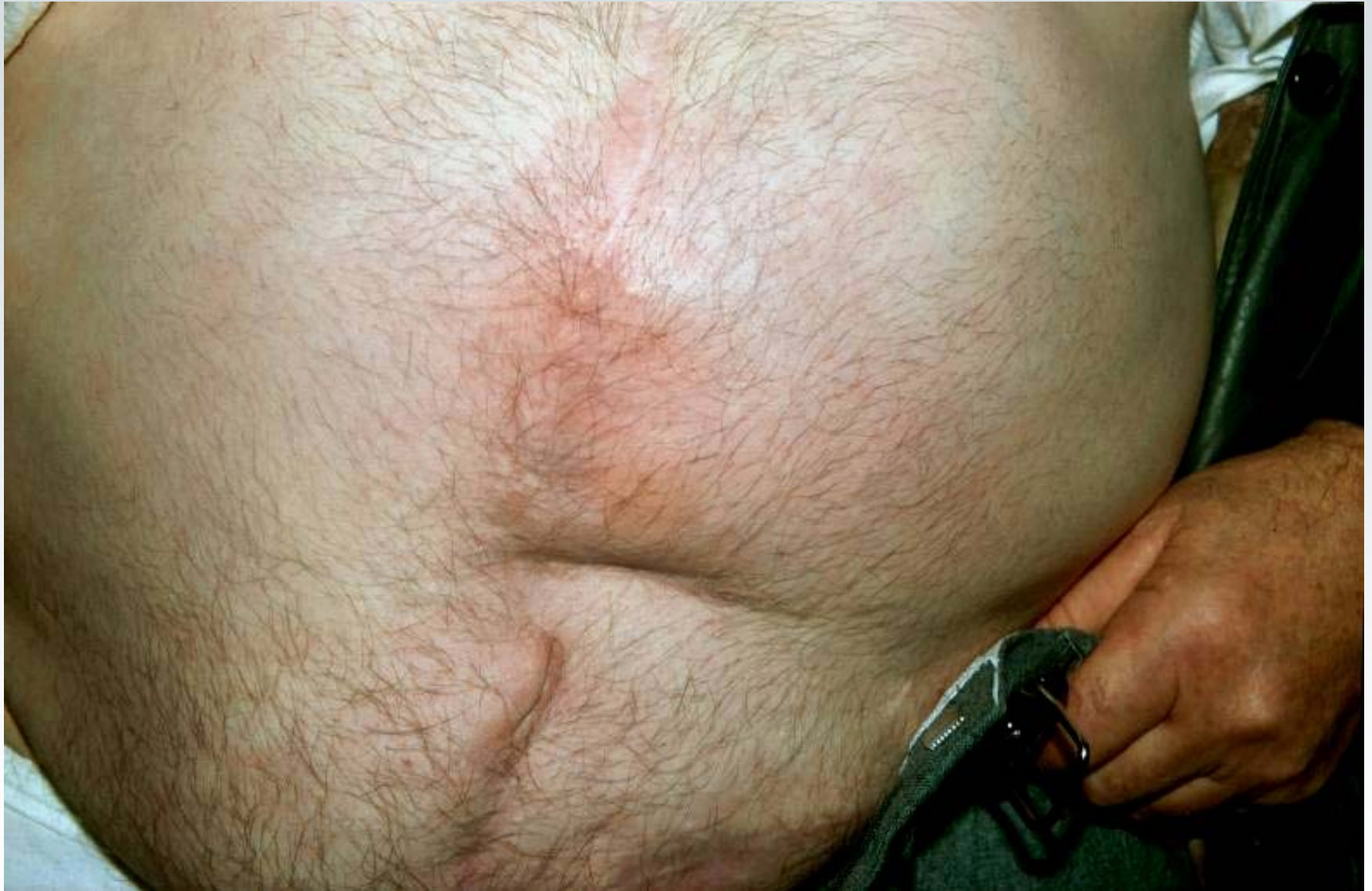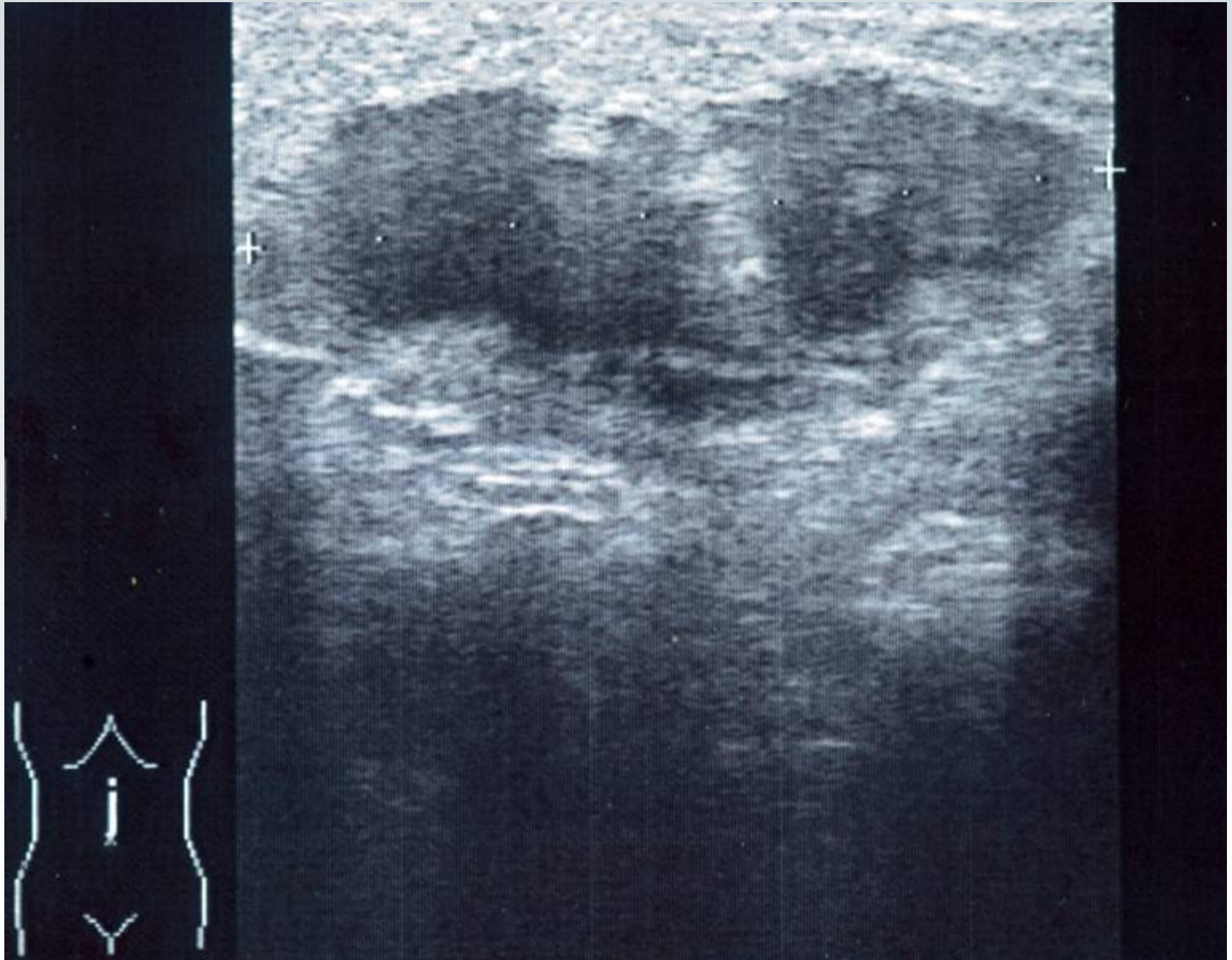
Akutes Abdomen

Pankreatitis

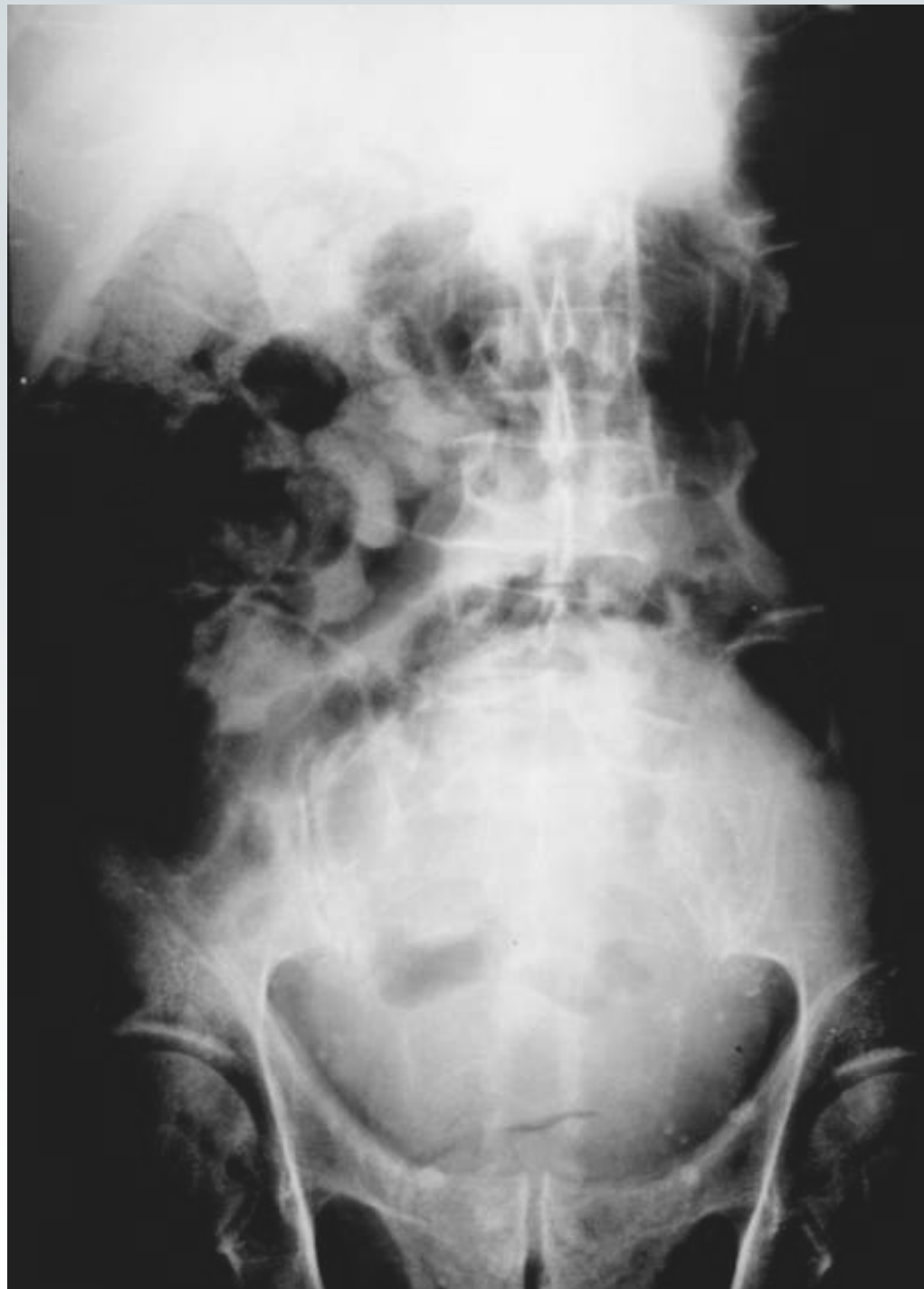







Akutes Abdomen



Akutes Abdomen ***"Pseudoperitonitis"***

- **Pleuritis, Pneumonie, Lungenembolie**
- **Herzinfarkt, Rechtsherzinsuffizienz**
- **Wirbelfrakturen (retroperit. Hämatom)**
- **Diabetes, Porphyrie**
- **Epilepsie**
- **Intoxikationen**

